



Informativeness of postmortem dynamics of skeletal muscles of dog and cat corpses for forensic veterinary diagnosis of death due to acute hypoxia

Ivan Yatsenko*

Doctor of Veterinary Sciences, Professor

State Biotechnological University

62341, 1 Akademichna Str., village Mala Danylivka, Ukraine

<https://orcid.org/0000-0001-8903-2129>

Roman Kazantsev

Postgraduate Student

State Biotechnological University

62341, 1 Akademichna Str., village Mala Danylivka, Ukraine

<https://orcid.org/0000-0002-4479-1516>

Abstract. The relevance of the study is conditioned by the need in the practice of forensic veterinary expertise to establish the statute of limitations for the occurrence of death of dogs and cats during the investigation of crimes against animal health and life. In this regard, the purpose of the study is to solve diagnostic forensic veterinary problems regarding the informative value of postmortem disorganisation of skeletal neck muscles of dog and cat corpses within 72 hours after the death of animals. The main methods of investigating the diagnostic information content of postmortem dynamics of skeletal muscles of dog and cat corpses for forensic veterinary determination of the conditions and prescription of death due to acute hypoxia are those that can be comprehensively considered the identified problem, in particular, Papenheim-Kryukov staining of smears, slides – hematoxylin and eosin, fluorescein isothiocyanate, and Shabadash staining. The forensic veterinary diagnostic significance of two expert criteria is justified: “the number of patterns of disorganisation of the neck muscles of dog and cat corpses” and “glycogen content in the neck muscles of dog and cat corpses”. It is proved that biotransformation of skeletal muscles occurs in the following sequence: during the first 24 hours after the death of the animal, postmortem stiffness of the

Suggested Citation:

Yatsenko, I., & Kazantsev, R. (2024). Informativeness of postmortem dynamics of skeletal muscles of dog and cat corpses for forensic veterinary diagnosis of death due to acute hypoxia. *Ukrainian Journal of Veterinary Sciences*, 15(1), 139-167. doi: 10.31548/veterinary1.2024.139.

*Corresponding author



Copyright © The Author(s). This is an open access article distributed under the terms of the Creative Commons Attribution License 4.0 (<https://creativecommons.org/licenses/by/4.0/>)

muscles of corpses occurs, accompanied by dehydration, compaction, contraction of myofibrils; muscle relaxation is observed from 24 to 48 hours after death, myofibrils are stretched and swollen; from 48 to 72 hours, autolysis of muscles is recorded under the influence of saprotrophs. It was found that the destruction of skeletal muscle tissue is more intense in the case of death due to suffocation compared to death from poisoning, and the destruction of muscle tissue is more dynamic in the case of death due to freezing compared to death caused by drowning in cold water. For the first time, the results obtained will contribute to solving diagnostic forensic veterinary tasks, in particular, establishing the statute of limitations and conditions for the occurrence of death of dogs and cats during the investigation by law enforcement agencies of crimes related to animal cruelty

Keywords: asphyxia; cytomorphological examination; histotopograms; destruction patterns; thanatogenesis; abuse

Introduction

The study of postmortem dynamics of organs and tissues of animal corpses is important for forensic veterinary diagnostics, as can accurately determine the time and cause of death of the animal. Analysing these changes also helps to identify possible cases of abuse or improper animal care. In addition, this study is relevant for ensuring justice, as it can reveal evidence of criminal acts, such as animal cruelty or illegal hunting. It helps in determining the exact time of death, which can be a key element in criminal investigations. Thus, post-mortem diagnostics of veterinary and forensic medicine is a necessary tool in the protection of animals and ensures the maintenance of law and order.

Questions of informative postmortem dynamics of various organs and tissues of animal corpses for forensic veterinary diagnosis of death for various reasons were analysed by a large number of researchers. Among them: J.J. Paltian *et al.* (2019) evaluated the duration of the postmortem interval by determining the activity of catalase and aminolevulinatase dehydratase in the liver, kidney, skeletal muscle, and brain tissues of Swiss mice; J. Abbate *et al.* (2022) found the informativeness of post-mortem changes in skeletal muscle electrical conductivity of *Dicentrarchus labrax* to estimate the duration of the postmortem period;

J. Geissenberger *et al.* (2021) investigated post-mortem degradation of skeletal limb protein in pigs; T. Du *et al.* (2018) characterised the metabolic profile of rat femoral muscle at different time periods after death; F.X. Shi *et al.* (2020) observed the expression of autophagy-related protein in rat muscle tissue after ante- and postmortem trauma; Z. Zheng *et al.* (2019) substantiated the relationship between electrical conductivity and chemical content of rat skeletal muscle impregnation solution to determine the duration of the postmortem period.

The achievements obtained contributed to solving some problems. According to reports R. Kazantsev & I. Yatsenko (2022) and M. Skrypka *et al.* (2023), the issue of finding informative criteria remains relevant, the use of which will allow a forensic veterinary expert to come to certain categorical conclusions when solving situational problems and argumentation of causal relationships. The lack of prospective morphological studies of muscle tissue of animal corpses, clarification of the significance of marker changes in its postmortem disorganisation during forensic veterinary diagnosis of causes of death and systematisation of scientifically based information in scientometric databases on these issues, necessitates in-depth research in this area. As noted by M. Lamri *et*

al. (2023) and G. Piegari *et al.* (2023), the study of skeletal muscles is promising in this context due to their histomorphological (fibre density) and histochemical (glycogen depot) features.

Thus, the lack of developed expert criteria for determining the time of death of animals of various species for postmortem phenomena negatively affects the practice of conducting forensic veterinary expertise, causing unjustified refusals to conduct it; substitution of forensic expertise for other procedural actions; raising questions that go beyond the competence of a forensic expert, etc.; and determined the purpose of this study – to substantiate the diagnostic information content of postmortem biotransformation of skeletal muscles of dog and cat corpses to establish the conditions and duration of the postmortem period for hypoxic thanatogenesis. In this regard, the experimental solution of these issues is of both theoretical and practical significance.

Materials and Methods

The subject of the study was the dynamics of post-mortem biotransformation of skeletal muscles within 72 hours after death from acute hypoxia in 28 animals (*Felis silvestris catus*, n=12; *Canis lupus familiaris*, n=16) in the absence of anamnesis data on zoonthroposes. The category of violent death was known in advance. The study was conducted at the State Biotechnological University during 2021-2023 in compliance with the requirements of DSTU EN ISO/IEC 17025:2019 (2021). During the modelling of hypoxic thanatogenesis, environmental climatic factors were reproduced in which, with a high probability, the corresponding type of animal death occurred.

All the cases under study were divided into four experimental groups according to the principle of the immediate cause of death of the animal (n=7 in the group). Each group contained corpses with the following distribution: by taxonomic species (cats, n=3; dogs, n=4),

sex (females, n=3; males, n=4), age (neonatal, n=2; mature, n=3; geriatric, n=2).

Group 1 included the corpses of animals whose death occurred due to intoxication with carbon monoxide or isoniazid. They were stored at a temperature of 18°C and a humidity of 59%. Group 2 included the corpses of animals that died from mechanical asphyxia or general overheating. They were placed in a thick plastic bag and stored at a temperature of 18°C and a humidity of 64%. Group 3 consisted of corpses of animals whose death occurred as a result of fluid aspiration during drowning or perinatal pneumopathy. They were stored in tap water at a temperature of plus 2°C and a humidity of 73%. Group 4 includes the corpses of animals that died from a general cold injury. They were stored at negative 18°C and 92% humidity.

Skeletal muscle samples from *mm. proprii colli* were taken from the corpses of animals of all experimental groups after forensic veterinary necropsy. The choice of object for this study is justified by three reasons. Firstly, the relatively easy availability of material selection. Secondly, even in fragmented animal corpses, there is a certain possibility of obtaining the necessary number of tissue samples. Thirdly, the muscles are sufficiently isolated from the destructive effects of the environment and putrefactive transformation by endogenous saprotrophs.

During the first day after the onset of animal death, a series of preparations were made from muscle necropsies. For cytomorphological examination, they were stained using the Papanheim-Kryukov method. For histological studies of muscles, samples from corpses were taken at the 48th and 72nd hours of follow-up using a special punch. Histological slides with a thickness of 6 microns from samples were made on a rotary Microtome MPS-2 (Ukraine) in accordance with the generally accepted method (Horalskyi *et al.*, 2015).

For general histomorphological examination at the final stage, the slides were stained

with hematoxylin and eosin. Fluorescein isothiocyanate staining with neutral glycerin immersion was used to indicate bacterial colonies. For the purpose of histochemical determination of muscle glycogen content, the slides were stained using the Shabadash method. All the glasses were air-dried. Using an optical microscope *Granum R50* (China), skeletal muscle cytograms were examined in 10×10 and 10×100 visual fields, and 10×20 and 10×40 microscope visual fields were used to study muscle histotopograms.

The results were evaluated within each day, comparing the previous data with the next and the first with the last in each study group. The most representative changes were photographed using the TouPCam UCMOS03100KPA digital nozzle (China) integrated with the microscope. The obtained information was analysed on a personal computer with the Windows 10 operating system. The resulting photos were processed using the Photo Frame Studio 3.0 software suite and the destruction patterns were evaluated according to the recommendations of R.E. Raskin *et al.* (2022). Patterns in this study were considered any elements of muscle fibre decomposition, in particular, cell destruction and bacterial colonies, which were analysed in dynamics on the obtained cytograms and histotopograms. Then, in the image editor Adobe Photoshop CS6, histograms of slides were created, additionally coloured according to Shabadash, which automatically displayed the perimeter of glycogen distribution over the image, expressed in pixels, according to the tinkorial brightness level. On the histograms, attention was drawn to the last two indicators of the gradation scale: the total number of pixels, which identifies the outlined area in logical units, and the median of the integrated density, which is equivalent to the average value of colour brightness. In statistical data, using the MS Office Excel 2016 software suite, arithmetic mean indicators were determined ($M \pm m$) and evaluated by the level of reliability (P).

All studies at different levels of structural organisation were conducted in Ukraine for the first time, in compliance with the principles of evidence-based veterinary medicine in the context of forensic veterinary expertise and in accordance with the principles of European Association for Animal Research (n.d.).

Results and Discussion

Applying a retrospective analysis of the nosological structure of *exitus letalis* among cats and dogs in veterinary medical institutions, it was found that decompensated hypoxia of various aetiologies is fatal in 7% of all cases of death of various categories, including due to acute respiratory distress syndrome, neonatal lung atelectasis, and aspiration pneumonitis. Two hours after the death of the animals, during their forensic veterinary sectional examination, it was determined that *mm. proprii colli* are dense to the touch, and the joints of the cervical vertebrae are almost not mobile.

Cytomorphological studies of muscle specimens from the corpses of cats from group 1, obtained 8 hours after death, revealed the preservation of their vital structure. Cytograms showed clusters of striated skeletal muscle fibres in the form of spindle-shaped strands located tightly (Fig. 1).

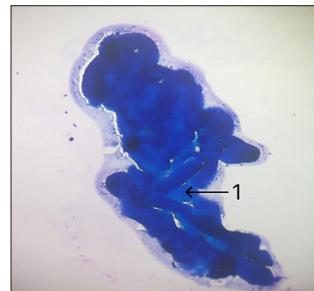


Figure 1. Cytogram of the skeletal muscle of the cat corpse from group 1, 8 hours after death
Notes: 1 – fibres of striated skeletal muscle. Eyepiece 10×lens 10, stained according to Papanheim-Kryukov
Source: developed by the authors

Myosimplasts are dark blue in colour, with pronounced transverse striation and clear edges. The nuclei of cells are oblong in shape, their chromatin is concentrated in the depths. The background of drugs is represented by singular erythrocytes around clusters of fibres. 16 hours after the death of cats from group 1, there are no optical changes in skeletal muscle. Cytological preparations contained accumulations of striated muscle fibres. Nuclei of elongated myosimplasts without morphological changes in karyolema, karyoplasm, and chromatin (Fig. 2). Transverse striation was found with clearly structured boundaries of their cytoarchitecture (Fig. 2). The cells were dark blue in colour, and some of them showed indistinct membranes. The background of drugs is a small number of erythrocytes.

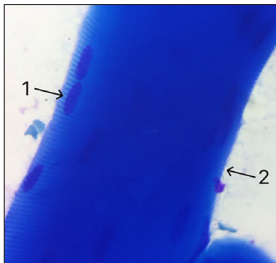


Figure 2. Cytogram of skeletal muscle of the cat corpse from group 1, 16 hours after death

Notes: 1 – nuclei in the middle of the muscle fibres; 2 – edges of the muscle fibre with clear borders. Eyepiece 10 × lens 100, stained according to Papanheim-Kryukov
Source: developed by the authors

24 hours after the death of cats from group 1, changes in muscle striation were visualised. On cytological preparations, muscle fibres are arranged in clusters. The shape of individual myosimplast nuclei is fragmented (Fig. 3). The cytoplasm of cells is coloured dark blue, and there is mostly no striation. The indistinct edges of the fibres were stained eosinophilic pink. Against the background of such destructive changes in the structure of muscle fibre cells,

isolated nuclei located outside the cytoplasm were observed.

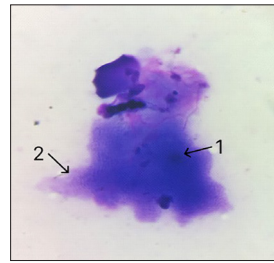


Figure 3. Cytogram of the skeletal muscle of the cat corpse from group 1, 24 hours after death

Notes: 1 – fragments of the muscle fibre nucleus; 2 – part of the muscle fibre with an altered internal structure. Eyepiece 10 × lens 100, stained according to Papanheim-Kryukov
Source: developed by the authors

8 hours after the onset of death of dogs of the group 1, the fibres of their skeletal muscle looked morphologically typical and retained their intravital structure. Dense accumulations of muscle fibres in the form of elongated strands were recorded on cytological preparations (Fig. 4). Myosimplasts are dark blue in colour, with well-defined transverse striation and edges. The nuclei are elongated in shape with tightly concentrated chromatin. The background of cytopreparations is represented by singular erythrocytes around clusters of fibres.

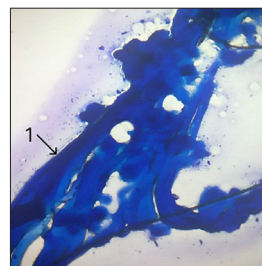


Figure 4. Cytogram of the skeletal muscle of the corpse of a dog from group 1, 8 hours after death

Notes: 1 – fibres of striated skeletal muscle. Eyepiece 10 × lens 10, stained according to Papanheim-Kryukov
Source: developed by the authors

In cytological preparations of muscle tissue from dogs from group 1, obtained 16 hours after death, there were almost no morphological changes in the muscles. The muscle fibres retained their striated structure and were arranged in clusters. Myosimplasts were coloured dark blue, and their edges remained clear (Fig. 5). The transverse striation is well expressed, the nuclei are oblong in shape without noticeable morphological changes in karyoplasm, karyolema, and chromatin. The background of the print preparation is represented by a small number of erythrocytes and isolated nuclei of myosimplasts.

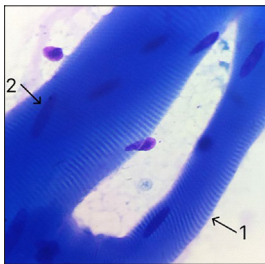


Figure 5. Cytogram of the skeletal muscle of the corpse of a dog from group 1, 16 hours after death
Notes: 1 – edges of the muscle fibre; 2 – nucleus in the middle of the muscle fibre. Eyepiece 10 × lens 100, stained according to Papenheim-Kryukov
Source: developed by the authors

24 hours after the onset of death of dogs from group 1, significant changes in the structure of muscle fibres were observed, which were placed in clusters on the slides. The cytoplasm of myosimplasts is coloured dark blue, their striation is mostly absent. The indistinct edges of the fibres change the tinkorial properties towards eosinophilic staining (Fig. 6). The sarcoplasm and individual nuclei in the middle of the fibres changed shape and structure. The background of cytological preparations is protein, grey in colour, represented by isolated nuclei of myosimplasts.

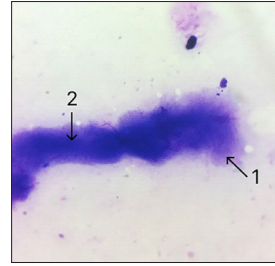


Figure 6. Cytogram of the skeletal muscle of the corpse of a dog from group 1, 24 hours after death
Notes: 1 – indistinct edges of the muscle fibre with pink cytoplasm; 2 – part of the muscle fibre with changes in the internal structure. Eyepiece 10 × lens 100, stained according to Papenheim-Kryukov
Source: developed by the authors

During cytomorphological examination of skeletal muscles of corpses of cats from group 2, it was found that as early as 8 hours after death, the muscle fibres looked morphologically typical (Fig. 7). However, a significant number of fibre nuclei located in isolation were found. Cytological preparations are represented by accumulations of striated skeletal muscle fibres in the form of elongated strands. The cells are coloured dark blue, with a slightly altered transverse striation. The boundaries of the sarcoplasm are clearly defined, the nuclei inside are oblong in shape with tightly concentrated chromatin. The background is represented by singular erythrocytes and a large number of extra-fibre nuclei.

16 hours after the death of cats from group 2, changes in skeletal muscle were visualised, which characterised the destruction of cell structure. In addition to compactly arranged striated muscle fibres, numerous nuclei located outside of them were found (Fig. 8). Myosimplasts are coloured dark blue, their edges are blurred, stained in light pink. The transverse striation was almost not observed in comparison with the samples obtained in the previous interval of the experiment. The cell nuclei were mostly not morphologically altered, but single

nuclei with a modified shape were also found. The background of cytological preparations is

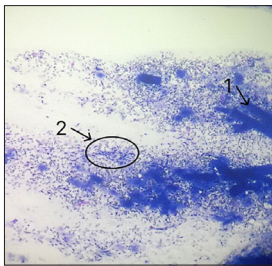


Figure 7. Cytogram of the skeletal muscle of the cat corpse from group 2, 8 hours after death
Notes: 1 – fibres of striated skeletal muscle; 2 – accumulations of separated nuclei of muscle fibres. Eyepiece 10 × lens 10, stained according to Papanheim-Kryukov
Source: developed by the authors

represented by a significant number of isolated nuclei and blood cells.

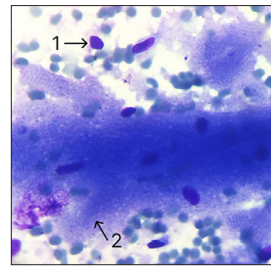


Figure 8. Cytogram of the skeletal muscle of the cat corpse from group 2, 16 hours after death
Notes: 1 – isolated nucleus of a muscle fibre; 2 – part of a muscle fibre with changes in its internal structure. Eyepiece 10 × lens 100, stained according to Papanheim-Kryukov
Source: developed by the authors

24 hours after the death of cats in group 2, significant changes in the structure of muscle fibres were observed. The preparations obtained during this period of time showed clusters of muscle fibres with dark blue cells. Their characteristic striation is completely absent, and the

edges of the fibres are indistinct (Fig. 9). The shape of the nuclei in the middle of the fibres is morphologically altered. The background of cytological preparations is protein, grey-blue in colour with a large number of fragmented myosin nuclei.

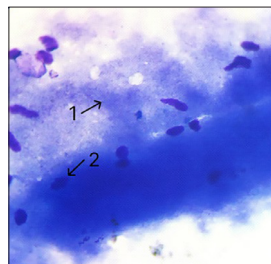


Figure 9. Cytogram of the skeletal muscle of the cat corpse from group 2, 24 hours after death
Notes: 1 – muscle fibre with complete loss of internal structure; 2 – fragments of the nucleus in the middle of the muscle fibre. Eyepiece 10 × lens 100, stained according to Papanheim-Kryukov
Source: developed by the authors

During the cytomorphological study of skeletal muscle imprints of corpses of dogs from group 2, it was found that 8 hours after death, the fibres are represented morphologically

typically, but with minor destruction of myosin nuclei and the formation of extra-fibre nuclear formations (Fig. 10). Cytological preparations contained accumulations of striated

skeletal muscle fibres in the form of elongated strands, in some of them the shape was destructively changed. Skeletal muscle fibres are coloured dark blue, mostly with clear transverse striation and edges. Myosymplast nuclei are elongated in shape with tightly concentrated chromatin. The background of cytological preparations is represented by singular erythrocytes and isolated non-destroyed nuclei.

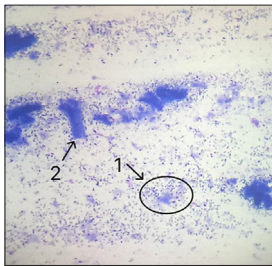


Figure 10. Cytogram of the skeletal muscle of the dog corpse from group 2, 8 hours after death
Notes: 1 – accumulation of isolated nuclei of muscle fibres; 2 – fibres of striated skeletal muscle with an altered shape. Eyepiece 10 × lens 10, stained according to Papanheim-Kryukov
Source: developed by the authors

At the 16th hour of the experiment, significant destructive changes in the shape of muscle fibres were detected in the corpses of dogs in group 2. The imprinted preparations contained clusters of striated muscle fibres and separated nuclei arranged in small clusters (Fig. 11). Myosymplasts are coloured dark blue, with blurred fibre edges and a light pink background around the edges. The transverse striation is somewhat blurred compared to samples obtained in previous time intervals. Local fibre regions were observed with significant structural changes in the form of a complete loss of internal structure. The nuclei are mostly without noticeable changes, but some of them are deformed. The background of cytological preparations is represented by isolated muscle fibre nuclei, erythrocytes, and endotheliocytes.

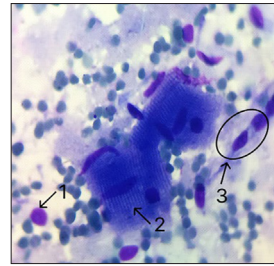


Figure 11. Cytogram of the skeletal muscle of the corpse of a dog from group 2, 16 hours after death
Notes: 1 – isolated nucleus of the muscle fibre; 2 – part of the muscle fibre with minor changes in the internal structure; 3 – accumulation of endotheliocytes. Eyepiece 10 × lens 100, stained according to Papanheim-Kryukov
Source: developed by the authors

After 24 hours of the experiment, it was found that myosymplasts of skeletal muscle corpses of dogs from group 2 underwent significant destructive changes not only in terms of shape, but also in their internal structure. Thus, microscopic examination of preparations revealed that the muscle fibres completely lost their transverse striation (Fig. 12). Myosymplasts are dark blue in colour, their edges are blurred, and the preserved nuclei are deformed. The background of such cytological preparations is grey-blue, represented mainly by fragments of isolated nuclei and protein debris.

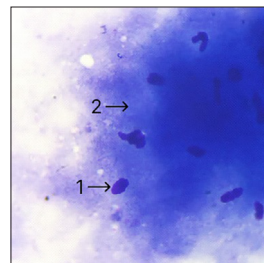


Figure 12. Cytogram of the skeletal muscle of the dog corpse from group 2, 24 hours after death
Notes: 1 – accumulation of destroyed muscle fibres; 2 – deformed nucleus of the muscle fibre. Eyepiece 10 × lens 100, stained according to Papanheim-Kryukov
Source: developed by the authors

Cytomorphological examination of the skeletal muscle tissue of the corpses of cats from group 3 revealed that at 8 hours after their death, the muscle fibres looked morphologically typical, but showed an increased number of extra-fibrous, separately located myosymplastic nuclei. The cellular composition of preparations is represented by clusters of myosymplasts of muscle fibres in the form of elongated strands (Fig. 13) and destroyed fibres with separately located nuclei.

Myosymplasts are dark blue in colour, with well-defined transverse striation and clear edges. The nuclei are elongated, and chromatin is placed compactly in them. The background of cytological preparations is

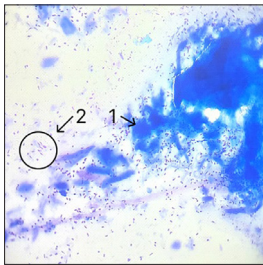


Figure 13. Cytogram of the skeletal muscle of the cat corpse from group 3, 8 hours after death

Notes: 1 – skeletal muscle fibre; 2 – cluster of detached myosymplastic nuclei. Eyepiece 10 × lens 10, stained according to Papenheim-Kryukov

Source: developed by the authors

24 hours after the death of cats in group 3, there were significant changes in the clarity of the edges of muscle fibres and the number of nuclei outside them (Fig. 15), and the severity of transverse striation. On the print preparations, a cluster of muscle fibres with sarcoplasm coloured dark blue is visible. Their visual striation is almost invisible, and the edges of the fibres are indistinct. The fibre nuclei are fragmented. The cytological background of

represented by singular erythrocytes and isolated nuclei of muscle fibres. 16 hours after the death of cats from group 3, characteristic changes in the structure of myosymplasts began to appear. Cytological preparations contained clusters of striated muscle fibres against the background of a small number of nuclei located outside them (Fig. 14). The fibres are turned dark blue, the contouring of their edges is reduced, the colour is eosinophilic, light pink. The severity of transverse striation is slightly reduced compared to previous samples. The nuclei of myosymplasts located in the sarcoplasm are oblong in shape without noticeable changes in karyolema, chromatin, and karyoplasm.

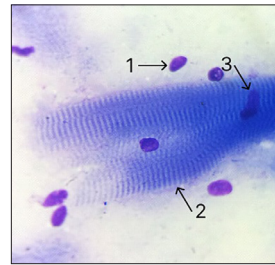

Figure 14. Cytogram of the skeletal muscle of the cat corpse from group 3, 16 hours after death

Notes: 1 – isolated nucleus of the muscle fibre; 2 – indistinct edges of the muscle fibre; 3 – nucleus in the middle of the muscle fibre. Eyepiece 10 × lens 100, stained according to Papenheim-Kryukov

Source: developed by the authors

such drugs is represented by a large number of nuclei isolated from sarcoplasm.

With regard to the dynamics of changes in the muscle tissue of dogs from group 3, 8 hours after death, it was proved that the muscle fibres were morphologically typical. However, a significant number of extra-fibre nuclei separated from the cytoplasm were observed. On such preparations, accumulations of striated skeletal muscle fibres in the form

of elongated strands are visually noticeable. The cytoplasm of myosimplasts is coloured dark blue. The transverse striation and edges are clearly defined (Fig. 16). The nuclei are

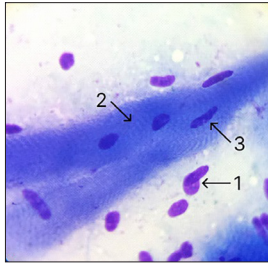


Figure 15. Cytochrome of the skeletal muscle of the cat corpse from group 3, 24 hours after death
Notes: 1 – nucleus of the muscle fibre separated from the sarcoplasm; 2 – striation of the muscle fibre; 3 – nucleus in the middle of the muscle fibre. Eyepiece 10 × lens 100, stained according to Papenheim-Kryukov
Source: developed by the authors

elongated in shape, and their chromatin is densely located. The background of cytopreparations is represented by erythrocytes in combination with separated nuclei.

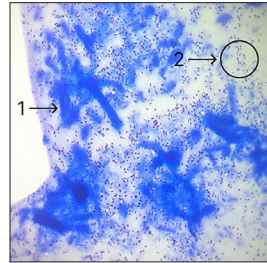


Figure 16. Cytochrome of the skeletal muscle of the dog corpse from group 3, 8 hours after death
Notes: 1 – fibres of striated skeletal muscle; 2 – accumulations of isolated nuclei of myosimplasts. Eyepiece 10 × lens 10, stained according to Papenheim-Kryukov
Source: developed by the authors

16 hours after the death of dogs in group 3, patterns of cell destruction began to appear in the skeletal muscle specimens. Cytological preparations contained clusters of individual muscle fibres with a significant number of nuclei separated from sarcoplasm (Fig. 17). The fibres are coloured dark blue, and the clarity of their edges is reduced. The severity of

transverse striation is slightly reduced or absent in some fibres. Areas with a modified structure and a light pink background along the contour were visualised. Most myosimplast nuclei are elongated without noticeable morphological changes in karyolema and chromatin. The cytological background is represented by isolated nuclei of muscle fibres.

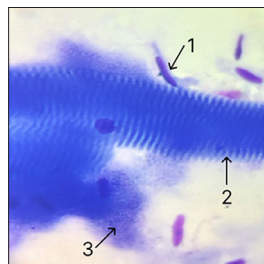


Figure 17. Cytochrome of the skeletal muscle of the dog corpse from group 3, 16 hours after death
Notes: 1 – the nucleus separated from the sarcoplasm; 2 – transverse striation of the muscle fibre; 3 – part of the muscle fibre with destructive changes in the internal structure. Eyepiece 10 × lens 100, stained according to Papenheim-Kryukov
Source: developed by the authors

The destructive changes that occurred in the skeletal muscle tissue of the corpses of dogs from group 3, 24 hours after death, were characterised by the presence of separated vascular endothelial cell nuclei from the cytoplasm (Fig. 18) and tintorial properties around the edges of fibres and their internal structure. The preparations contained accumulations of muscle fibres. Myosimplasts are dark blue in colour, with reduced striation, indistinct fibre edges, a small number of altered fibre nuclei and nucleoli. The cytological background is represented by isolated nuclei of muscle fibres and fragments of blood capillaries.

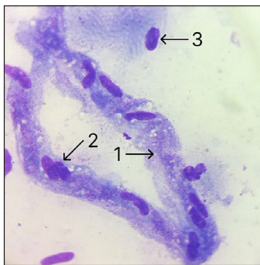


Figure 18. Cytogram of the skeletal muscle of the dog corpse from group 3, 24 hours after death
Notes: 1 – cytoplasm of capillary endotheliocytes; 2 – nuclei of capillary endotheliocytes; 3 – nucleus of muscle fibre with destructive changes. Eyepiece 10 × lens 100, stained according to Papenheim-Kryukov
Source: developed by the authors

According to cytomorphological changes in the muscle tissue of corpses of cats in group 4, it was found that 8 hours after their death, skeletal muscle fibres retained a morphologically typical structure. The preparations contained accumulations of striated skeletal muscle fibres in the form of elongated strands (Fig. 19). Myosimplasts are dark blue in colour, with pronounced transverse striation and clear edges. The nuclei are elongated, and their chromatin is densely located. The cellular background of such drugs is represented by singular erythrocytes.

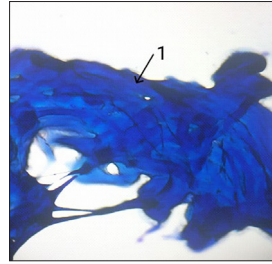


Figure 19. Cytogram of the skeletal muscle of the cat corpse from group 4, 8 hours after death
Notes: 1 – fibres of striated skeletal muscle. Eyepiece 10 × lens 10, stained according to Papenheim-Kryukov
Source: developed by the authors

At the same time, 16 hours after death, characteristic changes in the structure of skeletal muscle fibres of corpses of cats in group 4 were observed. Striated muscle fibres located in dense clusters were determined on the print preparations. Sarcoplasma is stained in a dark blue colour with a light pink background around the edges. The transverse striation is not clearly expressed (Fig. 20). The nuclei are oblong in shape without noticeable morphological changes in karyolema and chromatin. The background of cytological preparations is represented by nuclei located outside the visual contour of the sarcolemma of muscle fibres.

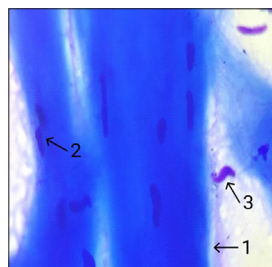


Figure 20. Cytogram of the skeletal muscle of the cat corpse from group 4, 16 hours after death
Notes: 1 – indistinct edges of the striated skeletal muscle fibre; 2 – nucleus of the muscle fibre; 3 nucleus of the muscle cell outside the skeletal fibre. Eyepiece 10 × lens 100, stained according to Papenheim-Kryukov
Source: developed by the authors

Twenty-four hours after the onset of death in cats from group 4, significant destructive changes were observed in their muscle tissue compared with the previous interval of the experiment. Thus, tightly placed and deformed muscle fibres were found on the impression preparations. Their sarcoplasm is coloured blue with completely lost banding (Fig. 21). The contours of muscle fibres were characterised by changes in tinctorial properties, a characteristic eosinophilic hue, and indistinct edges. The nuclei were visualised with altered karyolema,

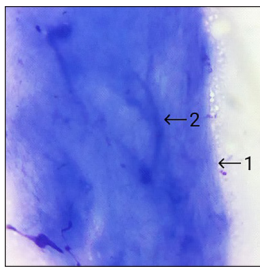


Figure 21. Cytogram of the skeletal muscle of the cat corpse from group 4, 24 hours after death
Notes: 1 – indistinct edges of skeletal muscle fibre; 2 – muscle fibre with lost striation. Eyepiece 10 × lens 100, stained according to Papenheim-Kryukov
Source: developed by the authors

Muscle tissue specimens obtained 16 hours after the death of dogs from group 4 are represented by clusters of striated muscle fibres. Their sarcoplasm turned dark blue, but the contours became eosinophilic. The striation and boundaries of the fibres are not

irregular geometric shape. However, their number against previously obtained samples is insignificant.

Cytological preparations of skeletal muscles of dogs in group 4 (8 hours after the death of dogs) contained dense clusters of striated skeletal muscle fibres in the form of elongated strands (Fig. 22). Sarcoplasm is coloured dark blue with pronounced transverse striation and clear edges. The nuclei of myosimplasts are also elongated, and the chromatin in the nucleoli is represented by condensed structures.

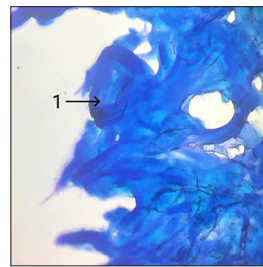


Figure 22. Cytogram of the skeletal muscle of the dog corpse from group 4, 8 hours after death
Notes: 1 – fibres of striated skeletal muscle. Eyepiece 10 × lens 10, stained according to Papenheim-Kryukov
Source: developed by the authors

clearly expressed (Fig. 23). A small number of karyol-altered myosimplast nuclei located in the middle of the fibres were recorded. The background of cytological preparations is represented only by isolated nuclei of skeletal muscle fibres.

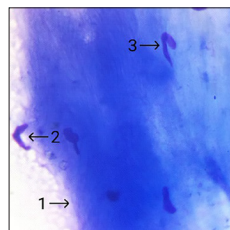


Figure 23. Cytogram of the skeletal muscle of the dog corpse from group 4, 16 hours after death
Notes: 1 – indistinct edges of the skeletal muscle fibre; 2 – nucleus outside the muscle fibre; 3 nucleus in the middle of the muscle fibre. Eyepiece 10 × lens 100, stained according to Papenheim-Kryukov
Source: developed by the authors

It was found that within a day after the death of dogs from group 4, significant destructive changes in the structure of skeletal fibres occurred. It was found that myosymplasts were located in the form of significantly deformed clusters. The sarcoplasm was coloured dark blue, its banding and optical boundaries were not visualised (Fig. 24). The shape of the indestructible fibre nuclei is oval. The background of cytological preparations is represented by single, fragmented nuclei of polygonal myosymplasts located outside their visual contour.

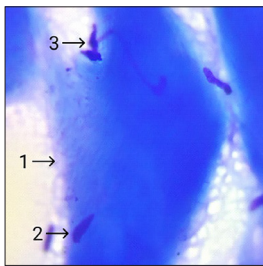


Figure 24. Cytogram of the skeletal muscle of the dog corpse from group 4, 24 hours after death
Notes: 1 – indistinct edges of the skeletal muscle fibre; 2 – intact nucleus of the muscle fibre; 3 – nucleus outside the muscle fibre. Eyepiece 10 × lens 100, stained according to Papenheim-Kryukov
Source: developed by the authors

According to the results of microscopy of skeletal muscles of corpses of dogs and cats of all experimental groups, it was proved that the degree of development of destructive changes after 24 hours of the postmortem period does not allow using the cytomorphological method to monitor further biotransformation of myosymplasts. Therefore, the focus of research was shifted to the tissue level of structural organisation of animal corpses.

On the 48th hour after the onset of death in cats from group 1, individual areas of slightly swollen, relaxed myofibrils were found in their skeletal muscles, which were tightly adjacent to

each other (Fig. 25), with small gaps between fibres. Total destruction of myofibrils was not observed. In the process of disorganisation of muscle tissue, there was a fairly rapid transition from their jamming to the stage of relaxation. As a result, some areas of myofibrils underwent pronounced postmortem contraction. Marginalisation of myosymplast nuclei in the form of their deformation was observed mainly among clusters located in sarcoplasm. Bacterial colonies formed around such clusters, which apparently enhanced further skeletal muscle autolysis (Fig. 26).

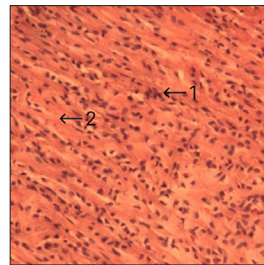


Figure 25. Histotopogram of the skeletal muscle of the cat corpse from group 1, 48 hours after death
Notes: 1 – densely located myofibrils; 2 – accumulation of myosymplast nuclei in the middle of the fibres. Eyepiece 10 × 40 lens, hematoxylin and eosin staining
Source: developed by the authors

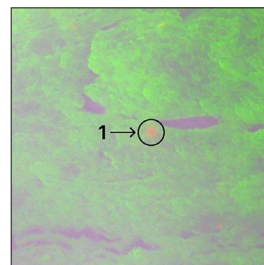


Figure 26. Histotopogram of the skeletal muscle of the cat corpse from group 1, 48 hours after death
Notes: 1 – bacterial colony. Eyepiece 10 × lens 20, immersion, fluorescein isothiocyanate staining
Source: developed by the authors

At 48 hours after the onset of death in dogs from group 1, significant structural changes were recorded in their skeletal muscles in the form of focal ruptures of individual myofibrils and individual muscle bundles. Isolated myosymplast nuclei were observed between deformed and preserved muscle fibres (Fig. 27), which also underwent destruction with a significant change in the shape of karyolema.

Loci of total destruction of muscle fibres changed their own tinctorial properties, which was reflected in the eosinophilic staining of such histological preparations. There was a

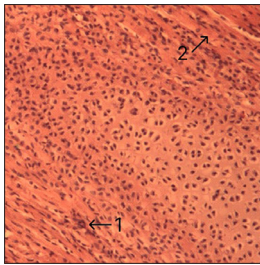


Figure 27. Histotopogram of the skeletal muscle of the corpse of a dog from group 1, 48 hours after death
Notes: 1 – accumulation of myosymplast nuclei in the middle of the fibres; 2 – densely placed myofibrils. Eyepiece 10 × 40 lens, hematoxylin and eosin staining
Source: developed by the authors

The histomorphological examination of skeletal muscle obtained from the corpses of cats and dogs from group 2, 48 hours after death, revealed patterns of destruction typical of the processes of deep autolysis of individual myofibril sections. Marginalisation of myosymplast nuclei was observed among clusters located mainly separately from the sarcoplasm, in the form of loss of their natural

natural loss of parallel arrangement of fibres and their significant deformation and fragmentation. Such destroyed areas were somewhat compacted (Fig. 27). Completely destroyed myofibrils also underwent fragmentation. Disorganisation of myofibrils was aggravated by the activation of enzymes, under the influence of which an amorphous mass was formed. The mass fraction in the rapid development of skeletal muscle autolysis processes was played by the bright development of saprotrophs (Fig. 28), which colonised not only on the surface of tissues, but also penetrated deep.

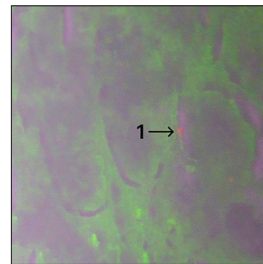


Figure 28. Histotopogram of the skeletal muscle of the corpse of a dog from group 1, 48 hours after death
Notes: 1 – bacterial colony. Eyepiece 10 × lens 20, immersion, fluorescein isothiocyanate staining
Source: developed by the authors

rounded shape. Bacterial colonies were formed around such clusters due to cross-contamination (Fig. 29, 30), which increased further disorganisation of muscle fibres. Most of the myofibrils were placed randomly on the area of histological preparations and underwent total decay. However, it should be noted that fragmentation of myofibrils covered only a small part of their total number.

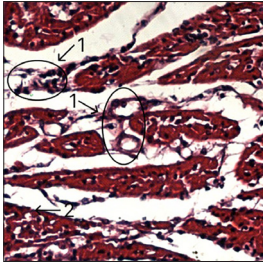


Figure 29. Histotopogram of the skeletal muscle of the cat corpse from group 2, 48 hours after death
Notes: 1 – bacterial colonies around marginalised myosymplast nuclei; 2 – fragmented myofibrils. Eyepiece 10 × 40 lens, hematoxylin and eosin staining
Source: developed by the authors

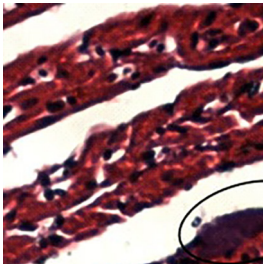


Figure 30. Histotopogram of the skeletal muscle of the dog corpse from group 2, 48 hours after death
Notes: 1 – bacterial colonies. Eyepiece 10 × 40 lens, hematoxylin and eosin staining
Source: developed by the authors

It is worth noting that histotopograms of skeletal muscles of cats and dogs 48 hours after the start of the experiment showed changes characteristic of the autolysis stage. Some of the fibres were represented by an “amorphous mass”, homogenised, and their transverse striation was not visually manifested. Destructive processes led to the destruction of myofibrils. A significant number of them acquired somewhat thickened, wavy shapes. Their sarcomeric structure remained partially preserved. Further intensive growth of saprotrophs occurred to the

same extent as in cat corpses (Fig. 31), and in the dog corpses (Fig. 32).

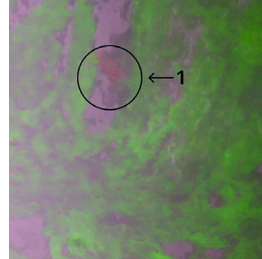


Figure 31. Histotopogram of the skeletal muscle of the cat corpse from group 2, 48 hours after death
Notes: 1 – bacterial colonies. Eyepiece 10 × lens 20, immersion, fluorescein isothiocyanate staining
Source: developed by the authors

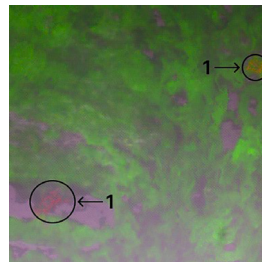


Figure 32. Histotopogram of the skeletal muscle of the dog corpse from group 2, 48 hours after death
Notes: 1 – bacterial colonies. Eyepiece 10 × lens 20, immersion, fluorescein isothiocyanate staining
Source: developed by the authors

The study of skeletal muscle samples from cats and dogs from group 3, 48 hours after death, revealed the formation of large gaps due to the crystallisation of fluid localised between myofibril cords and separated muscle fibres. Isolated myosymplast nuclei were arranged in clusters (Fig. 33), marginalised (Fig. 34). Liquid crystals created unevenly placed cavities of different areas in the layers of sarcoplasm, which were deformed due to compression.

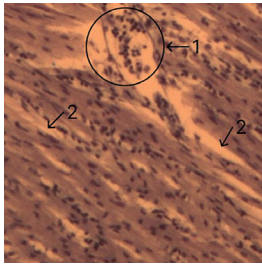


Figure 33. Histotopogram of the skeletal muscle of the cat corpse from group 3, 48 hours after death

Notes: 1 – clusters of isolated, marginalised nuclei of myosimplasts; 2 – gaps between muscle filaments.

Eye-piece 10 × 40 lens, hematoxylin and eosin staining

Source: developed by the authors

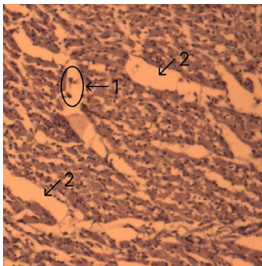


Figure 34. Histotopogram of skeletal muscle of a dog corpse from group 3, 48 hours after death

Notes: 1 – isolated nuclei of myosimplasts; 2 – gaps between muscle filaments. *Eye-piece 10 × 40 lens, hematoxylin and eosin staining*

Source: developed by the authors

The histotopograms of muscle fibre samples from the corpses from group 3 cats, 48 hours after death, looked “loose”. The nuclei located in the sarcoplasm of muscle fibres were in a state of total pycnosis. During histochemical identification of glycogen, it was found that it is represented by a fine-grained, deep substance with inherent oxyphilic properties (Fig. 35a), which evenly filled most of the area of histological slides not only in the cavities, but also was located directly in the sarcoplasm of myosym-

plasts. Gaps formed in the liquid crystallisation sites were observed between the fibres of individual filaments (Fig. 35b). At the stage of muscle relaxation, the phenomenon of «loosening» of fibres was observed, which is explained by the action of autolytic processes.

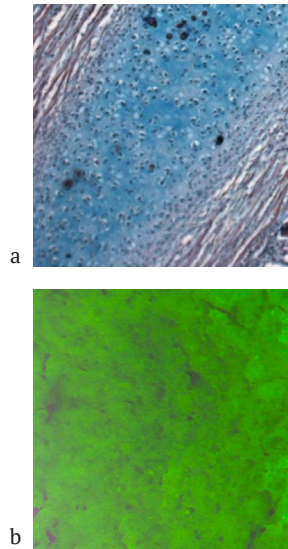


Figure 35. Histotopogram of the skeletal muscle of the cat corpse from group 3, 48 hours after death

Notes: *eye-piece 10 × lens 20; a – hematoxylin and eosin staining, Shabadash post-staining; b – immersion, fluorescein isothiocyanate staining*

Source: developed by the authors

The histotopograms of muscle fibre samples obtained 48 hours after the death of dogs in group 3 showed some loosening of their structure. The nuclei of myosimplasts were pycnotic, the contours of karyolema were not visually distinguished. The damaging effect of tissue fluid crystals on the sarcolemma was manifested by the development of gaps around the contours of individual muscle filaments. During histochemical identification of glycogen, it was noted that it is evenly distributed over almost the entire area of histological slides and is

represented by a fine-grained lumpy substance with a characteristic oxyphilic colour (Fig. 36a).

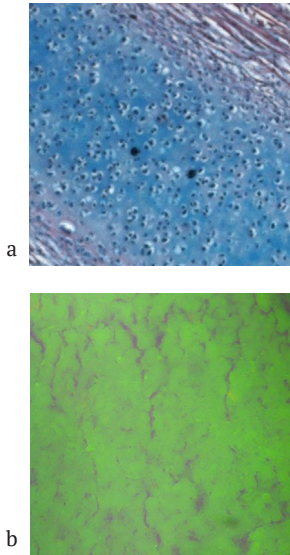


Figure 36. Histotopogram of skeletal muscle of a dog corpse from group 3, 48 hours after death
Notes: *a* eyepiece 10 × lens 20, hematoxylin and eosin staining, Shabadash post-staining; *b* eyepiece 10 × lens 20, immersion, fluorescein isothiocyanate staining
Source: developed by the authors

Small gaps were observed between the individual fibres of deformed myofibrils, which formed in the areas of crystallisation of tissue fluid, as a result of which the muscles looked somewhat “loose” (Fig. 36b). 48 hours after death, rapid development of numerous liquid crystals was recorded in tissue samples from the corpses of cats and dogs in group 4, which caused a pronounced total deformation of myofibrils with their rough fragmentation (Fig. 37a). However, their transverse striation was well defined. The muscle fibres were subjected to significant compression, as a result of which some of them looked torn (Fig. 37b).

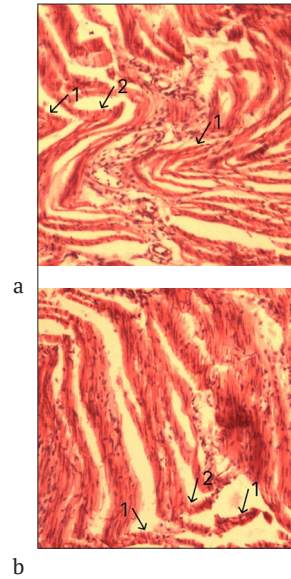


Figure 37. Histotopogram of the skeletal muscle of the cat corpse from group 4, 48 hours after death
Notes: *a* – 1 – fragments of torn myofibrils; 2 – gaps between myofibrils. Eyepiece 10 × lens 40, hematoxylin and eosin staining; *b* – 1 – fragments of torn myofibrils; 2 – gaps between myofibrils. Eyepiece 10 × 40 lens, hematoxylin and eosin staining
Source: developed by the authors

Total crystallisation was accompanied by development both inside and outside the sarcoplasm. As a result of the destructive effect of liquid crystals, in the deep layers of skeletal muscles, there was a significant deformation of both muscle fibre bundles and tissue layers between the bundles of myofibrils. The marginal nuclei of myosymplasts remained outside the visual contour of the sarcolemma and were located on histological slides in the form of isolated clusters. Histochemical studies of striated skeletal muscle of cats from group 4, 48 hours after death, revealed that the glycogen substance was localised on histological slides in some limited areas and was a

fine-grained substance with a characteristic oxyphilic colour (Fig. 38).

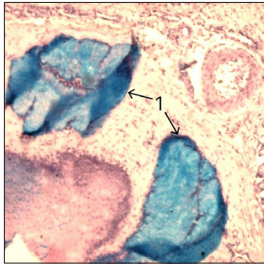


Figure 38. Histotopogram of the skeletal muscle of the cat corpse from group 4, 48 hours after death

Notes: 1 – deep structures of glycogen. Eyepiece 10 × lens 20, hematoxylin and eosin staining, Shabadash post-staining

Source: developed by the authors

Significant morphological changes were recorded not only in the surface, but also in the deep layers of muscle tissue. The destructive effect of liquid crystals formed a significant number of large voids (Fig. 39) between myofibrils. Histomorphological examination of skeletal muscles revealed a significant amount of not only surface deformed muscle fibres, but also intramuscular crystallisation with increasing spaces between fibres and sarcolemma breaks.

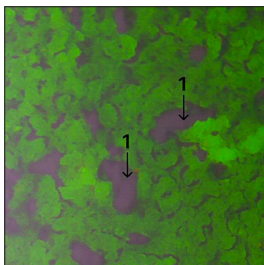


Figure 39. Histotopogram of the skeletal muscle of the cat corpse from group 4, 48 hours after death

Notes: 1 – gaps between myofibrils. Eyepiece 10 × lens 20, immersion, fluorescein isothiocyanate staining

Source: developed by the authors

Histochemical studies of striated skeletal muscle from the corpses of dogs in group 4, 48 hours after death, showed that the glycogen substance on histological slides was localised in some limited areas and was represented by a fine-grained substance with a characteristic oxyphilic colour (Fig. 40).

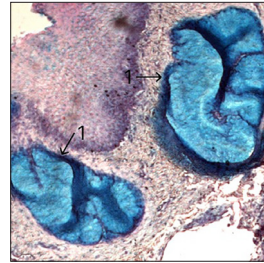


Figure 40. Histotopogram of skeletal muscle of a dog corpse from group 4, 48 hours after death

Notes: 1 – deep structures of glycogen. Eyepiece 10 × lens 20, hematoxylin and eosin staining, Shabadash post-staining

Source: developed by the authors

During histomorphological microscopy of skeletal muscles, homogenisation of muscle fibres, a significant number and sufficiently large voids were recorded (Fig. 41) between bundles of muscle fibres in places of fluid crystallisation.

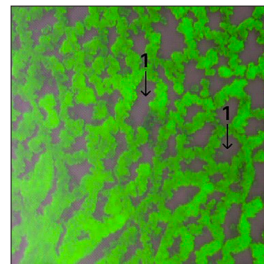


Figure 41. Histotopogram of skeletal muscle of a dog corpse from group 4, 48 hours after death

Notes: 1 – gaps between myofibrils. Eyepiece 10 × lens 20, immersion, fluorescein isothiocyanate staining

Source: developed by the authors

Microscopy of histotopograms of skeletal muscles obtained from the corpses of cats and dogs from group 1 at 72 hours after death was similar. The identified patterns indicated deep autolytic processes. Diffuse destruction of the architectonics of muscle fibres caused the development of homogeneous, fragmented, with no signs of histological differentiation, shapeless structures. Areas of destructive changes were found in the form of significant gaps in myofibrils with the development of wide layers between the endomysium and lysis of marginal karyoplasma residues, which had the same general character in the skeletal muscles of cats and dogs. Individual bacteria (Fig. 42) against the background of chaotic enzymatic reactions contributed to further disorganisation of the tissue and manifestly indicated the stage of putrefactive biotransformation of skeletal muscles.

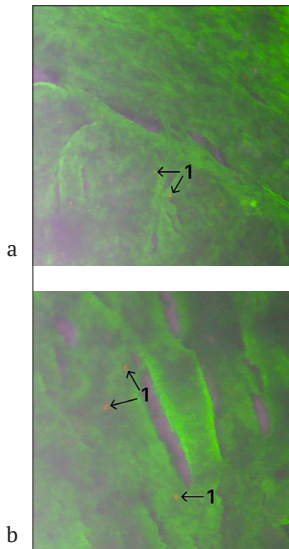


Figure 42. Histotopogram of skeletal muscle of corpse from group 1, 72 hours after death
Notes: a – cat corpse; b – dog corpse; 1 – individual bacteria. Eyepiece 10 × lens 20, immersion, staining with fluorescein isothiocyanate
Source: developed by the authors

72 hours after the onset of death of cats and dogs from group 2, the manifestation of cross-contaminated saprotrophs covered with a common film was observed (Fig. 43).

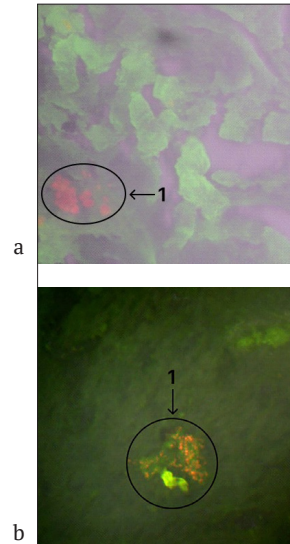


Figure 43. Histotopogram of skeletal muscle of corpse from group 2, 72 hours after death
Notes: a – cat corpse; b – dog corpse; 1 – bacterial colonies. Eyepiece 10 × lens 20, immersion, fluorescein isothiocyanate staining
Source: developed by the authors

Such colonies were recorded in the expanded layers between myofibrils in the same way in histotopograms of muscle tissue from cats and dogs. Patterns of putrefactive biotransformation were found in the form of significant changes in histoarchitectonics and the order of placement of deformed muscle fibres that are subject to diffuse fragmentation and total destruction. In the nuclei of myosymplasts, lysis of the remnants of the totally destroyed karyoplasm and karyolema was observed. Microscopy of histological specimens revealed deep processes of autolysis on the part of the sarcoplasm with structurally destroyed

endomysium and significant ruptures of muscle fibre bundles. This degree of autolysis indicates the final stage of disorganisation of muscle tissue, characterised by diffuse deep homogenisation of the tissue with the formation of an amorphous substance.

According to the results of histomorphological studies of skeletal muscles of corpses of cats from group 3, 72 hours after death, it was found that liquid crystals formed under the influence of low temperature were characterised by significantly smaller sizes, were found in larger quantities and were evenly located over the entire area of histological slides. There were practically no breaks in the integrity of muscle fibres, and the myofibrils themselves were placed tightly, sometimes with slight undulation (Fig. 44). Bacterial contaminants and fibre breaks in the transverse direction were not observed, and the layers between them were insignificant.

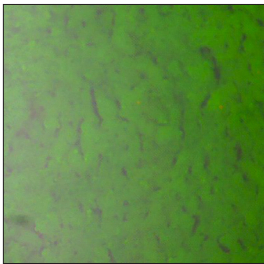


Figure 44. Histotopogram of skeletal muscle of the cat corpse from group 3, 72 hours after death

Notes: eyepiece 10 × lens 20, immersion, fluorescein isothiocyanate staining

Source: developed by the authors

During histochemical identification of glycogen, it was found that it is localised mainly in the centre of the histological slide area in the form of a fine-grained deep substance with oxyphilic staining (Fig. 45).

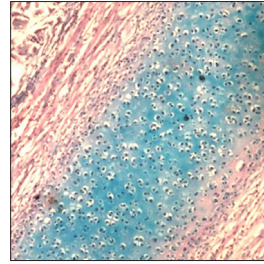


Figure 45. Histotopogram of skeletal muscle of the cat corpse from group 3, 72 hours after death

Notes: eyepiece 10 × lens 20, hematoxylin and eosin staining, Shabadash post-staining

Source: developed by the authors

According to the results of histomorphological studies of skeletal muscles of dog corpses from group 4, 72 hours after death, it was found that liquid crystals formed under the influence of low temperature caused structural changes, as a result of which myofibrils loosened. Between the bundles of muscle fibres, slits filled with liquid crystals were formed, followed by deformation of the fibres, which acquired more rounded shapes (Fig. 46).

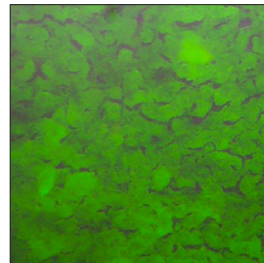


Figure 46. Histotopogram of skeletal muscle of a dog corpse from group 3, 72 hours after death

Notes: eyepiece 10 × lens 20, immersion, fluorescein isothiocyanate staining

Source: developed by the authors

There were practically no breaks in the integrity of muscle fibres, and the myofibrils themselves were placed tightly, sometimes with slight undulation. The number of fibre deformations and sarcolemma breaks in the deep layers of the muscles was significantly less than in the surface muscles. Bacterial contamination and fibre breaks in the transverse direction were not observed, and the gaps between them remained insignificant. During histochemical identification of glycogen, it was found that it is localised mainly in the centre of the histological slide area and is represented by a fine-grained deep substance with oxyphilic staining (Fig. 47).

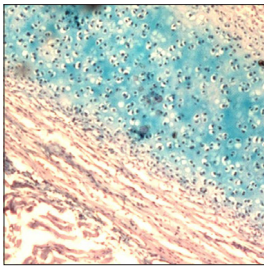


Figure 47. Histotopogram of skeletal muscle of a dog corpse from group 3, 72 hours after death
Notes: eyepiece 10 × lens 20, hematoxylin and eosin staining, Shabadash post-staining
Source: developed by the authors

As a result of histomorphological studies of skeletal muscles of cats from group 4, after 72 hours of postmortem period, it was found that there were no patterns of bacterial contamination at the onset of death under such conditions. However, numerous fluid crystals were formed evenly between the muscle fibres and bundles, which damaged the sarcolemma and caused severe deformation of the myofibrils (Fig. 48).

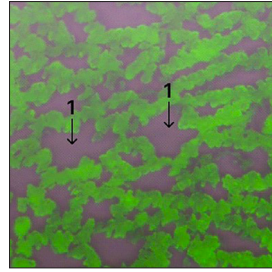


Figure 48. Histotopogram of the skeletal muscle of the cat corpse from group 4, 72 hours after death
Notes: 1 – gaps between myofibrils. Eyepiece 10 × lens 20, immersion, fluorescein isothiocyanate staining
Source: developed by the authors

The residues of the deep glycogen substance on histological slides were localised in areas with a small area and defined as a fine-grained substance with an oxyphilic colour (Fig. 49).

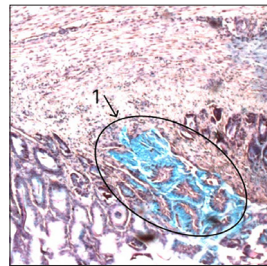


Figure 49. Histotopogram of the skeletal muscle of the cat corpse from group 4, 72 hours after death
Notes: 1 – condensed glycogen structures. Eyepiece 10 × lens 20, hematoxylin and eosin staining, Shabadash post-staining
Source: developed by the authors

In the case of histomorphological studies of skeletal muscles of dog corpses from group 4, no bacterial contamination was detected after 72 hours of postmortem. Numerous liquid crystals formed in the fabric under such conditions

caused compression of the fibres, their breaks and deformation. Due to prolonged exposure to excessively low temperatures, shrinkage processes occurred in the muscle tissue, which contributed to the development of large voids between the muscle fibres (Fig. 50).

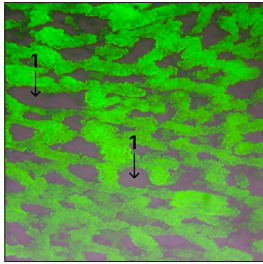


Figure 50. Histotopogram of the skeletal muscle of the dog corpse from group 4, 72 hours after death
Notes: 1 – gaps between myofibrils. Eyepiece 10 × lens 20, immersion, fluorescein isothiocyanate staining
Source: developed by the authors

Glycogen residues in the deep substance on histological slides were localised in areas with a small area as a fine-grained substance with oxophilic staining (Fig. 51).

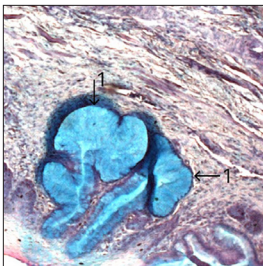


Figure 51. Histotopogram of the skeletal muscle of the dog corpse from group 4, 72 hours after death
Notes: 1 – condensed glycogen structures. Eyepiece 10 × lens 20, hematoxylin and eosin staining, Shabadash post-staining
Source: developed by the authors

As a result of the conducted studies, it was established that disorganisation of skeletal muscles of corpses of cats and dogs of all experimental groups developed in the following sequence and in the corresponding time ranges of the postmortem period: muscle stiffening, muscle relaxation, and muscle destruction.

Researchers like T. Du *et al.* (2018), B.P.H. Righetti *et al.* (2022) and R. Liu *et al.* (2022), note the importance of morphological changes in animal organisms observed in various types of injuries and poisoning. However, their research shows that these morphological changes are mainly caused by chaotic enzymatic reactions and a lack of energy resynthesis in cells. This means that after damage or poisoning, the body's cells can go into a state of chaos, where enzymatic reactions become disorganised and uncontrolled. This can lead to the destruction of cellular structures and organs. In addition, the influence of saprotrophs (organisms that decompose organic substances) can play an important role in the processes of thanatogenesis. Saprotrophs can actively decompose organic substances, which can lead to the build-up of toxic products and further deterioration of the body's condition.

Despite the variety of factors that can cause injury or poisoning, the researchers also emphasise that the main link of thanatogenesis in animals is the development of mixed hypoxia and cerebral anoxia, as stated by G. Piegari *et al.* (2019), A.F.M. Botelho *et al.* (2020) and M.A. King *et al.* (2021). Hypoxia indicates insufficient oxygen supply to the cells, and cerebral anoxia means a lack of oxygen for the brain. These conditions can result from various types of injuries or poisoning and can lead to serious disorders in the body. It is proved that the intensity of the manifestation of patterns of postmortem disorganisation of skeletal neck

muscles of corpses of dogs and cats was directly dependent on the influence of environmental conditions and the nature of fatal damaging factors, which is reflected in Table 1.

Table 1. Dynamics of skeletal neck muscle disorganisation patterns (units) of dog and cat corpses in the time ranges of the postmortem period

Time range (hours)	Dog corpses (n=16)				Cat corpses (n=12)			
	Group 1	Group 2	Group 3	Group 4	Group 1	Group 2	Group 3	Group 4
2-8	-	2.66 ±0.20	10.07 ±0.11	16.53 ±0.09	-	2.56 ±0.16	11.83 ±0.22	14.87 ±0.25
8-16	0.91 ±0.07	6.71 ±0.34***	16.07 ±0.09***	18.59 ±0.12***	0.70 ±0.12	6.64 ±0.36***	13.86 ±0.08***	22.37 ±0.14***
16-24	1.50 ±0.09**	11.36 ±0.71***	16.70 ±0.06***	22.93 ±0.06***	1.50 ±0.15**	11.77 ±0.58***	16.16 ±0.05***	23.40 ±0.54
24-48	2.49 ±0.13***	16.69 ±0.89*	17.79 ±0.07***	27.93 ±0.41***	1.66 ±0.10	13.76 ±0.29*	18.33 ±0.04***	27.09 ±0.55**
48-72	3.17 ±0.10***^^	22.10 ±0.78***^^^	18.47 ±0.04***^^	38.54 ±0.16***^^^	2.91 ±0.32***^^	22.84 ±1.15***^^^	18.71 ±0.04***^^	36.74 ±0.43***^^^

Notes: * $P < 0.05$, ** $P < 0.01$, *** $P < 0.001$ compared to the indicators of the previous study interval within the experimental group; ^ $P < 0.05$, ^^ $P < 0.01$, ^^ $P < 0.001$ compared between the first and last indicators within the experimental group

Source: developed by the authors

The data in Table 1 show that there are common patterns of postmortem neck muscle disorganisation in dog and cat corpses. In all experimental groups of dog corpses, quantitative indicators significantly increased during the corresponding time intervals of observation, but with different intensity. Similar to changes in dog corpses, in all study groups of cat corpses, muscle fibre biotransformation rates also increased significantly during the corresponding follow-up time periods. The intensity of such growth is variable and was directly dependent on the conditions of death of the animal.

W. Li *et al.* (2023) note that under the influence of hydrolases, the hydrogen index of muscle tissue changes, favourable conditions are created for contamination with bacteria, which cause further biotransformation and autolysis of skeletal muscles, which explains these phenomena. W. Zhu *et al.* (2021) argue that post-mortem autolysis of muscle tissue is caused by the destructive effects of a number

of enzymes that cause skeletal muscle stiffness, their progressive destruction, and accumulation of catabolism products. However, the study suggests that the destructive effects of enzymes are interrelated. Their role in the corresponding time ranges for the development of post-mortem disorganisation of cellular and tissue components of muscles varies.

Based on the results of histochemical staining according to Shabadash, the pattern of a gradual decrease in the glycogen content by the indicator of its distribution over the area of the histotopogram is proved. N. Wenzlow *et al.* (2023) note that glycogen, especially in hypothermia, is sensitive to impaired muscle oxygenation, and, therefore, it is a predictor of the development of tissue hypoxia, which is accompanied by a slowdown in phosphorylation, which is consistent with obtained data. The variability of glycogen content directly depended on the duration of the post-mortem period, if the death of the animal was

caused by excessive exposure to low ambient temperatures. In connection with the results obtained, it can be assumed that at the beginning of general hypothermia of the animal, the changes that occur are reversed, which is consistent with the results obtained by C-C. Liao *et al.* (2016) and P. Listos *et al.* (2017).

Based on the results of histogram evaluation, it was detailed that the enzymatic processes of glycogenolysis during prolonged exposure to excessively low temperatures were slower in dog corpses (Fig. 52 a, b) and cats (53 a, b) from group 3 compared to such changes in the corpses of animals from group 4.

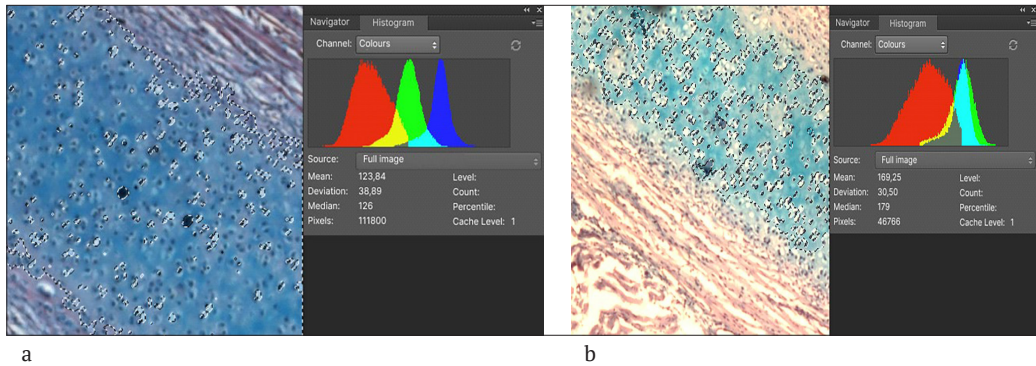


Figure 52. Histological preparation of skeletal muscle of a dog corpse from group 3 and histogram of glycogen distribution

Notes: a – 48 hours after death, b – 72 hours after death.

Source: developed by the authors

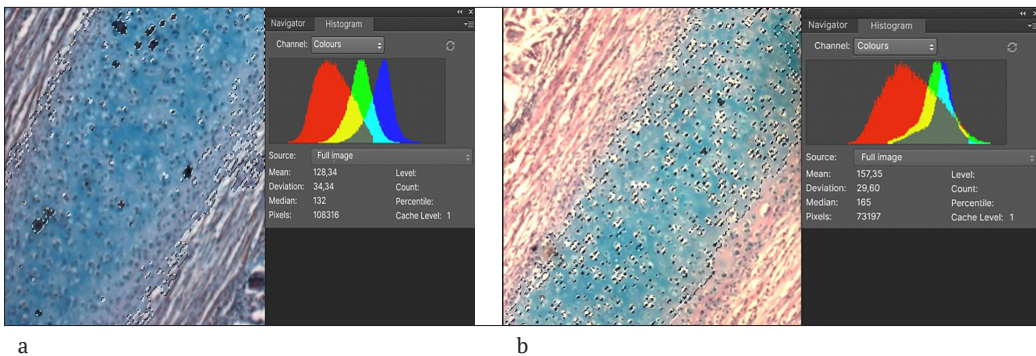


Figure 53. Histological specimen of skeletal muscle from a cat corpse from group 3 and histogram of glycogen distribution

Notes: a – 48 hours after death, b – 72 hours after death

Source: developed by the authors

According to histochemical studies of skeletal muscles of dog (Fig. 54 a, b) and cat (Fig. 55 a, b) corpses from group 4 found that the vast majority of glycogen was

decomposed to low-molecular-weight compounds over the time range – from 48 up to 72 hours after the death of animals from freezing.

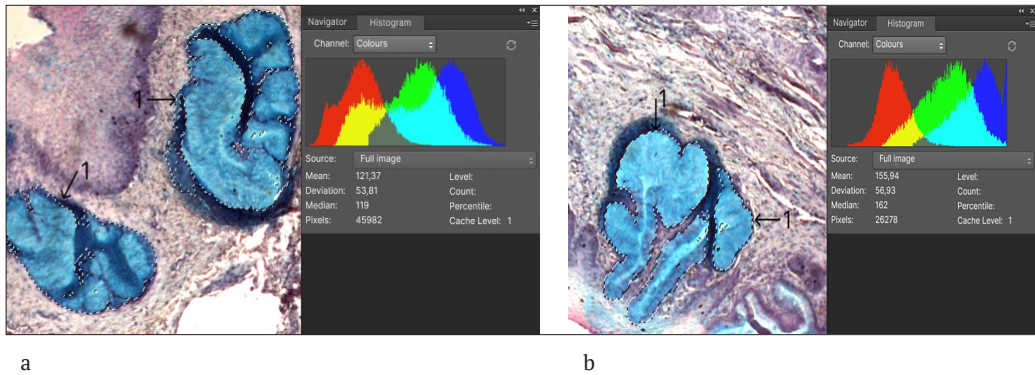


Figure 54. Histological preparation of skeletal muscle of a dog corpse from group 4 and histogram of glycogen distribution

Notes: a – 48 hours after death, b – 72 hours after death; 1 – condensed glycogen structures
Source: developed by the authors

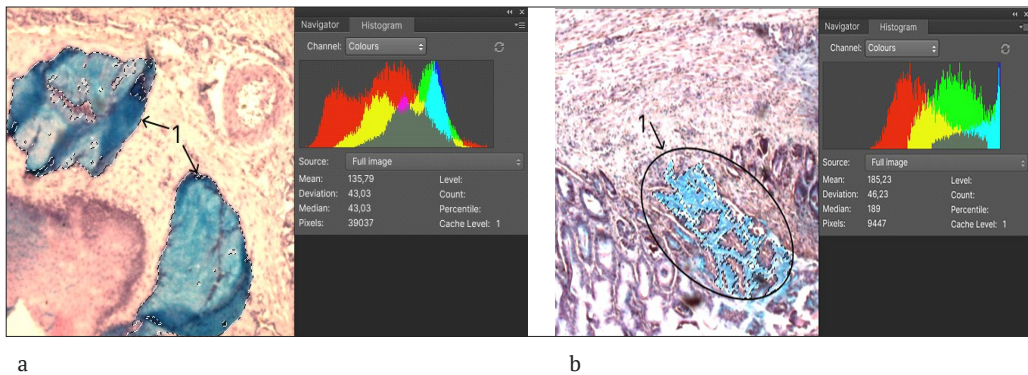


Figure 55. Histological preparation of skeletal muscle of the cat corpse from group 4 and histogram of glycogen distribution

Notes: a – 48 hours after death, b – 72 hours after death; 1 – condensed glycogen structures
Source: developed by the authors

The results of quantitative changes in glycogen content in the neck myosimplasts of dogs and cats whose death occurred under conditions of general hypothermia were characterised by a tendency to a rapid decrease in the level of the latter. They were directly dependent on the increase in the duration of death. Therefore, their authors considered them ba-

sic. The established facts about the informative value of postmortem biotransformation of skeletal muscles of animal corpses to find out the causes and duration of the post-mortem period for hypoxic thanatogenesis should be applied in the practical activities of a forensic veterinary expert to solve situational problems with similar adverse consequences.

Conclusions

The results of postmortem biotransformation of skeletal muscles of animal corpses are important for elucidating the causes and duration of the postmortem period for hypoxic thanatogenesis in dogs and cats. The “intermediate” values of the dynamics of the indicators of the patterns of disorganisation of the skeletal muscles of the neck of dogs and cats, statistically reflected in different time ranges of the early postmortem period, outline the identified regular trends and allow diagnosing the time of death of the animal during the first three days of the postmortem period according to two forensic veterinary criteria: “the number of patterns of disorganisation of the neck muscles of dog and cat corpses” and “the level of glycogen content in the neck muscles of dog and cat corpses” with maximum approximation and minimum error, which, according to the principles of evidence-based veterinary medicine, correspond to expert information.

It is proved that the biotransformation of skeletal muscles of all the studied animal corpses proceeds in the same direction from the stage of postmortem stiffness, through the stage of muscle relaxation to their final autolysis. However, the attention is focused on the different duration of such stages, depending on the conditions of death. Postmortem changes in muscle tissue up to 24 hours after the onset of animal death are accompanied

by its dehydration, compaction, and contraction of myofibrils. Skeletal muscle relaxation occurs between 24 and 48 hours after death and is characterised by stretching and swelling of the fibres. Under the influence of saprotrophs and autolytic processes, deep changes in the structure and composition of muscle fibres occur in the interval from 48 to 72 hours after the death of animals. For the first time in Ukraine, based on the results of a study of the dynamics of structural and biochemical changes in symplasts of skeletal neck muscles of dogs and cats, an algorithm was developed, the value of which consists of in the use of the identified relationship between the degree of disorganisation and the 72-hour time range after the onset of animal death in order to solve forensic veterinary diagnostic problems.

In the future, a promising area is to investigate the informative value of other than-atognomonic criteria for determining the causes and time of death of dogs and cats during a comprehensive forensic veterinary assessment of the phenomena of biotransformation of corpses, considering their various conditions.

Acknowledgements

None.

Conflict of Interest

None.

References

- [1] Abbate, J., Grifò, G., Capparucci, F., Arfuso, F., Savoca, S., Cicero, L., Consolo, G., & Lanteri, G. (2022). Postmortem electrical conductivity changes of *Dicentrarchus labrax* skeletal muscle: Root mean square (RMS) parameter in estimating time since death. *Animals (Basel)*, 12(9), article number 1062. doi: [10.3390/ani12091062](https://doi.org/10.3390/ani12091062).
- [2] Botelho, A.F.M., Machado, A.M.D., da Silva, R.H.S., Faria, A.C., Machado, L.S., Santos, H., Braga, S.D.M., Torres, B.B.J., Miguel, M.P., Chaves, A.R., & Melo, M.M. (2020). Fatal metaldehyde poisoning in a dog confirmed by gas chromatography. *BMC Veterinary Research*, 16(1), article number 139. doi: [10.1186/s12917-020-02348-w](https://doi.org/10.1186/s12917-020-02348-w).

- [3] DSTU ISO/IEC 17025:2019. (2021). *General requirements for the competence of testing and calibration laboratories*. Retrieved from <http://surl.li/rmsby>.
- [4] Du, T., Lin, Z., Xie, Y., Ye, X., Tu, C., Jin, K., Xie, J., & Shen, Y. (2018). Metabolic profiling of femoral muscle from rats at different periods of time after death. *PLoS ONE*, 13(9), article number e0203920. doi: [10.1371/journal.pone.0203920](https://doi.org/10.1371/journal.pone.0203920).
- [5] European Association for Animal Research. (n.d.). Retrieved from <https://www.eara.eu/animal-research-law>.
- [6] Geissenberger, J., Ehrenfellner, B., Monticelli, F.C., Pittner, S., & Steinbacher, P. (2021). Dismembered porcine limbs as a proxy for postmortem muscle protein degradation. *International Journal of Legal Medicine*, 135(4), 1627-1636. doi: [10.1007/s00414-021-02571-6](https://doi.org/10.1007/s00414-021-02571-6).
- [7] Horalskyi, L.P., Khomych, V.T., & Kononskyi, O.I. (2015). *Fundamentals of histological technique and morphofunctional methods of research in norm and at pathology*. Zhytomyr: "Polissia".
- [8] Kazantsev, R., & Yatsenko, I. (2022). Forensic veterinary diagnosis of dog's fatal poisoning with anticoagulant rodenticide – bromadiolone. *Scientific Bulletin of Veterinary Medicine*, 1(173), 120-136. doi: [10.33245/2310-4902-2022-173-1-120-136](https://doi.org/10.33245/2310-4902-2022-173-1-120-136).
- [9] King, M.A., Alzahrani, J.M., Clanton, T.L., & Laitano, O.A. (2021). Preclinical model of exertional heat stroke in mice. *Journal of Visualized Experiments*, 1(173). doi: [10.3791/62738](https://doi.org/10.3791/62738).
- [10] Lamri, M., Malva, A.D., Djenane, D., Albenzio, M., & Gagaoua, M. (2023). First insights into the dynamic protein changes in goat Semitendinosus muscle during the post-mortem period using high-throughput proteomics. *Meat Science*, 202, article number 109207. doi: [10.1016/j.meatsci.2023.109207](https://doi.org/10.1016/j.meatsci.2023.109207).
- [11] Li, W., Xing, Y., Gan, L., Peng, W., & Deng, S. (2023). Exploring the value of microorganisms in the appendix for inferring postmortem interval in Sprague-Dawley rats using high-throughput sequencing. *Journal of Forensic Sciences*, 68(1), 163-175. doi: [10.1111/1556-4029.15173](https://doi.org/10.1111/1556-4029.15173).
- [12] Liao, C.C., Chang, Y.S., Yang, S.Y., & Chou, R.G.R. (2016). Post-mortem proteolysis and tenderisation are more rapid and extensive in female duck breast muscle. *British Poultry Science*, 57(6), 734-739. doi: [10.1080/00071668.2016.1209736](https://doi.org/10.1080/00071668.2016.1209736).
- [13] Listos, P., Gryzinska, M., Batkowska, J., Dylewska, M., Dudzinska, E., & Piorkowski, J. (2017). Preliminary study on the estimation of the time of death in animals based on microflora development in a canine's gastrocnemius muscle. *Medycyna Weterynaryjna*, 73(4), 229-233. doi: [10.21521/mw.5677](https://doi.org/10.21521/mw.5677).
- [14] Liu, R., Wang, Q., Zhang, K., Wu, H., Wang, G., Cai, W., Yu, K., Sun, Q., Fan, S., & Wang, Z. (2022). Analysis of postmortem intestinal microbiota successional patterns with application in postmortem interval estimation. *Microbial Ecology*, 84(4), 1087-1102. doi: [10.1007/s00248-021-01923-4](https://doi.org/10.1007/s00248-021-01923-4).
- [15] Paltian, J.J., da Fonseca, C.A.R., Pinz, M.P., Luchese, C., & Wilhelm, E.A. (2019). Post-mortem interval estimative through determination of catalase and Δ -aminolevulinic acid dehydratase activities in hepatic, renal, skeletal muscle and cerebral tissues of Swiss mice. *Biomarkers*, 24(5), 478-483. doi: [10.1080/1354750X.2019.1619837](https://doi.org/10.1080/1354750X.2019.1619837).
- [16] Piegari, G., De Pasquale, V., d'Aquino, I., De Biase, D., Caccia, G., Campobasso, C. P., Tafuri, S., Russo, V., & Paciello, O. (2023). Evaluation of muscle proteins for estimating the post-mortem interval in veterinary forensic pathology. *Animals (Basel)*, 13(4), article number 563. doi: [10.3390/ani13040563](https://doi.org/10.3390/ani13040563).

- [17] Piegari, G., De Biase, D., d'Aquino, I., Prisco, F., Fico, R., Ilsami, R., Pozzato, N., Genovese, A., & Paciello, O. (2019). Diagnosis of drowning and the value of the diatom test in veterinary forensic pathology. *Frontiers in Veterinary Science*, 6, article number 404. doi: [10.3389/fvets.2019.00404](https://doi.org/10.3389/fvets.2019.00404).
- [18] Raskin, R.E., Meyer, D., & Boes, K.M. (2022). *Canine and feline cytopathology: A color atlas and interpretation*. Amsterdam: Elsevier.
- [19] Righetti, B.P.H., Lima, D., Dias, V.H.V. Mattos, J.J., Piazza, C.E., Vilas-Boas, L. O.B., Alves, T.C., Almeida, E.A., Lüchmann, K.H., & Bainy, A.C.D. (2022). Life after death? Exploring biochemical and molecular changes following organismal death in green turtles, *Chelonia mydas* (Linnaeus, 1758). *Chemosphere*, 308, article number 136569. doi: [10.1016/j.chemosphere.2022.136569](https://doi.org/10.1016/j.chemosphere.2022.136569).
- [20] Shi, F.X., Li, P., Lu, H.L., Li, N., Du, Q.X., Wang, Y.Y., & Sun, J.H. (2020). Expression of autophagy-associated protein in rat muscle tissues after antemortem and postmortem injury. *Fa Yi Xue Za Zhi*, 36(3), 293-298. doi: [10.12116/j.issn.1004-5619.2020.03.001](https://doi.org/10.12116/j.issn.1004-5619.2020.03.001).
- [21] Skrypka, M., Boyko, Y., Zapeka, I., & Golovan, K. (2023). The practice of forensic-veterinary examination of psycho-emotional stress in the genesis of insufficiency and death of animals. *Agrarian Bulletin Black Sea Littoral*, 106, 14-22. doi: [10.37000/abbsl.2023.106.02](https://doi.org/10.37000/abbsl.2023.106.02).
- [22] Wenzlow, N., Mills, D., Byrd, J., Warren, M., & Long, M.T. (2023). Review of the current and potential use of biological and molecular methods for the estimation of the postmortem interval in animals and humans. *Journal of Veterinary Diagnostic Investigation*, 35(2), 97-108. doi: [10.1177/10406387231153930](https://doi.org/10.1177/10406387231153930).
- [23] Zheng, Z., Zhai, X.D., Xia, Z.Y., Li, Y.L., Zhao, L.L., Liu, H.L., & Mo, Y.N. (2019). Relationship between electrical conductivity and chemical content of rat skeletal muscle impregnating solution and postmortem interval. *Fa Yi Xue Za Zhi*, 35(5), 572-575. doi: [10.12116/j.issn.1004-5619.2019.05.011](https://doi.org/10.12116/j.issn.1004-5619.2019.05.011).
- [24] Zhu, W., Zhai, X., Zheng, Z., Sun, K., Yang, M., & Mo, Y. (2021). New contributions to the relationship between sequential changes of ATP-related metabolites and post-mortem interval in rats. *Legal Medicine (Tokyo)*, 48, article number 101809. doi: [10.1016/j.legalmed.2020.101809](https://doi.org/10.1016/j.legalmed.2020.101809).

Інформативність постмортальної динаміки скелетних м'язів трупів собак і котів для судово-ветеринарної діагностики смерті внаслідок гострої гіпоксії

Іван Володимирович Яценко

Доктор ветеринарних наук, професор
Державний біотехнологічний університет
62341, вул. Академічна, 1, с. Мала Данилівка, Україна
<https://orcid.org/0000-0001-8903-2129>

Роман Геннадійович Казанцев

Аспірант
Державний біотехнологічний університет
62341, вул. Академічна, 1, с. Мала Данилівка, Україна
<https://orcid.org/0000-0002-4479-1516>

Анотація. Актуальність дослідження зумовлена потребою у практиці судово-ветеринарної експертизи встановити давність настання смерті собак і котів під час розслідування злочинів проти здоров'я і життя тварин. У зв'язку з цим мета роботи – це вирішення діагностичних судово-ветеринарних завдань щодо інформативності постмортальної дезорганізації скелетних м'язів шиї трупів собак і котів упродовж 72 годин після смерті тварин. Основними методами дослідження діагностичної інформативності постмортальної динаміки скелетних м'язів трупів собак і котів для судово-ветеринарного встановлення умов і давності настання смерті внаслідок гострої гіпоксії є ті, за якими можна комплексно розглянути виокремлену проблему, зокрема, фарбування мазків-відбитків за Папенгеймом-Крюковим, слайдів – гематоксилином та еозином, флуоресцеїна ізотіоціанатом і за Шабдашем. Обґрунтовано судово-ветеринарне діагностичне значення двох експертних критеріїв: «кількість патернів дезорганізації м'язів шиї трупів собак і котів» і «вміст глікогену в м'язах шиї трупів собак і котів». Доведено, що біотрансформація скелетних м'язів відбувається у наступній послідовності: упродовж перших 24 годин після смерті тварини настає посмертне заляккання м'язів трупів, що супроводжується дегідратацією, ущільненням, скороченням міофібрил; розслаблення м'язів спостерігається з 24 до 48 години після смерті, міофібрили розтягнуті й набряклі; з 48 до 72 години під впливом сапротрофів реєструється аутоліз м'язів. Встановлено, що деструкція скелетної м'язової тканини відбувається інтенсивніше у разі смерті внаслідок задушення порівняно зі смертю від отруєння, а деструкція м'язової тканини динамічніша у разі смерті внаслідок замерзання порівняно зі смертю, спричиненою утопленням у холодній воді. Вперше отримані результати сприятимуть вирішенню діагностичних судово-ветеринарних завдань, зокрема, встановленню давності та умов настання смерті собак і котів під час розслідування правоохоронними органами злочинів стосовно жорстокого поводження з тваринами

Ключові слова: асфіксія; цитоморфологічне дослідження; гістотопограми; патерни деструкції; танатогенез; жорстоке поводження