



## Microstructural analysis of meat and internal organs of broiler chickens using a probiotic biological product

Alona Bogatko\*

Graduate Student

Bila Tserkva National Agrarian University  
09117, 8/1 Soborna Sq., Bila Tserkva, Ukraine  
<https://orcid.org/0000-0001-8089-5884>

Mykola Utechenko

PhD in Veterinary Sciences, Associate Professor  
Bila Tserkva National Agrarian University  
09117, 8/1 Soborna Sq., Bila Tserkva, Ukraine  
<https://orcid.org/0000-0003-3747-9054>

**Abstract.** Probiotic preparation containing bacteria of the genus *Bacillus subtilis* and *Bacillus licheniformis* used for feeding broiler chickens to improve feed digestion, nutrient absorption, increase immune status and productivity, and for the prevention and treatment of various poultry diseases. The purpose of the study is to conduct histological tests of broiler chicken slaughter products when they were administered a probiotic biologic medical product in doses of: 0.5 g, 2.0, and 4.0 g per 10 dm<sup>3</sup> of water. The material was examined by the histological method. It was found that the muscle fibres in the pectoralis major are of the same type, evenly directed, the cytoplasm of muscle fibres is moderately eosinophilic, uniformly light pink, and minor layers of adipose tissue are found between the bundles of muscle fibres. The morphological architectonics of the heart muscle are preserved, cardiomyocytes are homogeneous and have a clear orientation. The microstructure of the liver of broiler chickens is unchanged: hepatocytes are collected in the same type of groups; the central veins are desolate; the cytoplasm of these cells is homogeneous, clear, and pink; the nuclei are weakly basophilic. In the spleen, the follicular structure is formed, leukocytes are diffusely placed at different stages of differentiation; vessels in significant numbers, thickened, of different calibre. The cuticle of the muscular part of the stomach contains the epithelial layer, the volume part of the connective tissue base layer is revealed; muscle fibres

### Suggested Citation:

Bogatko, A., & Utechenko, M. (2024). Microstructural analysis of meat and internal organs of broiler chickens using a probiotic biological product. *Ukrainian Journal of Veterinary Sciences*, 15(1), 24-47. doi: 10.31548/veterinary1.2024.24.

\*Corresponding author



are located under the mesenchymal base of the cuticle. Lungs by morphological structure have bronchial tubes throughout the structure, which contain blood cells. According to the results of the conducted studies, a beneficial effect of a probiotic biological product at a dose of 4.0 g/10 dm<sup>3</sup> of water on the morphology of the pectoralis major and internal organs of broiler chickens was established. Therefore, a probiotic at a dose of 4.0 g/10 dm<sup>3</sup> of water during the drinking of broiler chickens can be recommended to increase productivity and produce safe slaughter products. The practical significance of the results obtained is to determine the features of the effect of feeding poultry with different doses of probiotics on the microstructure of its slaughter products, which is important for obtaining the best effect from its use

**Keywords:** poultry; pectoralis major; slaughter products; histological studies; morphology; probiotic

## Introduction

The poultry industry uses modern intensive technologies for the production of poultry slaughter products, in particular, more than 120 million tonnes of chicken, turkey, duck, and quail meat are produced per year. However, due to the intensive nature of modern poultry farming, there are problems with the well-being of poultry, the impact on the environment, and the economic stability of the country. Therefore, it is necessary to develop modern systems for monitoring and controlling the maintenance of poultry, and well-being, in particular, improving the diet of feeding with the use of probiotic drugs (excluding antibiotics), and monitoring the production of poultry slaughter products and their safety. A.S. George & A.S.H. George (2023) pointed out that a modern monitoring and control system – the HACCP system – has been widely implemented in accordance with the requirements of the National Food Management Standard ISO 22000:2018 and the international food standard *Global Food Safety Initiative (GFSI)*.

Probiotics, prebiotics, and synbiotics have had significant positive effects not only on human health, but also on animal health, according to A. Rousseaux *et al.* (2023), in particular on the functions of internal organs, muscle

tissue, and intestinal mucosa, where the composition of beneficial microorganisms was modulated – *Bifidobacteria* and *Firmicute*. The use of probiotics has led to positive results in the prevention and treatment of a significant number of diseases, such as infectious diseases, malignant tumours, allergies, etc. When planning the development of poultry processing enterprises, it is necessary to consider the impact of their functioning on the environment. R. Kler *et al.* (2022) found that during the production of high-quality and safe meat of broiler chickens, it is necessary to ensure proper sanitary and hygienic conditions for their maintenance, feeding, and well-being. S. Tavaniello *et al.* (2023) proved a significant effect of the synbiotic drug “PoultryStar”, when fed to broiler chickens, on increasing body weight, carcass yield, improving the quality indicators of meat and offal, in particular morphological ones.

J. Lei *et al.* (2022) noted a significant effect of the gut microbiota of broiler chickens on some indicators of meat quality, in particular, moisture retention capacity and structure. Therefore, it is necessary to use probiotic drugs during poultry feeding, which will affect the state of the intestinal microflora. Y. Zhao *et al.* (2020) claimed that when feeding broiler

chickens a dietary probiotic *Bacillus licheniformis* H2 was noted to increase their growth, improve the morphological characteristics of the intestine, liver, and other internal organs. Safety and quality of poultry meat, as noted by D. Shalginbayev *et al.* (2022), can be determined not only by the content of moisture, fat, dry matter, etc., but also confirmed by histological studies during meat production and storage. The researchers established morphological changes in poultry meat when it was frozen at a temperature of negative  $(18\pm 2)^{\circ}\text{C}$ , which occurred during transportation. Researchers also developed a colorimetric method for identifying defrosted poultry meat by processing it with current and gas, which was used to establish falsification of the thermal state of poultry meat due to repeated freezing. F. Abdulkhalig & A.D. Sabow (2023) evaluated the morphological characteristics of poultry slaughter products, considering the effectiveness of the pre-slaughter state of poultry, the degree of exsanguination of carcasses, the composition of feed for feeding and the quality of poultry meat.

A.P. Paliy *et al.* (2020) pointed out the importance of conducting histological studies of meat raw materials and poultry slaughter products, since this method can confirm the safety and quality of meat products. V.G. Stoyanovsky *et al.* (2020) claimed that the addition of humic acids and the probiotic “Laktin” with plant-based preparations to the diet of broiler chickens increased the immunological status of the body, increased the safety of poultry, and the level of productivity. The morphological structure of the poultry intestinal tissue was characterised by the presence of immune structures, which affected the growth and development of broiler chickens during the rearing period. The Regulation of the European Union No. 1381 (2019) stipulates that monitoring the safety of meat and slaughtered products should be carried out transparently, considering the

sustainability of risk assessment in the food and feed chains. Currently, the use of probiotic biological product “Subtiform” is relevant in the production of broiler chicken meat.

The purpose of the study is to conduct a microstructural analysis of the pectoralis major muscle of broiler chickens and internal organs (heart, spleen, liver, stomach muscle tissue, lungs) after feeding probiotic biologics to broiler chickens in different doses.

### **Literature Review**

The use of antibiotics in the rearing of broiler chickens is harmful to their health, due to the irrational use and accumulation of residues in poultry meat and the appearance of antibiotic-resistant strains of microorganisms. Q. Zhu *et al.* (2021) searched for feed additives that are functional and beneficial for the health of broiler chickens and affect their growth and productivity. The researchers preferred to develop diets containing probiotics, prebiotics, emulsifiers, organic acids, essential oils, enzymes, etc.

Use of enzymatic products, probiotics, and prebiotics as indicated by G. Vinderola *et al.* (2023) and J. Choi *et al.* (2023) brought health benefits to animals and humans, considering their microbiological and chemical properties, and also had a positive effect on the microstructure of internal organs and muscle tissue. M.A. Arain *et al.* (2022) showed that probiotics added to feeding broiler chickens affected weight gain, organ growth, and development of digestive organs, muscle tissue, and their morphological composition. F.U. Memon *et al.* (2022) claimed that probiotic preparations were easily mixed with feed and water, improved feed intake by broiler chickens and their immunity, digestive process, increased nutrient absorption, had antimicrobial effects, and did not negatively affect the morphological parameters of the carcass and internal organs.

R. Jha *et al.* (2023) pointed out that improving the efficiency of feeding broiler chickens, maintaining the physiological health of poultry, and the morphological structure of meat and internal organs was influenced by the state of the gastrointestinal tract and immune system. Therefore, to regulate the process of feed digestion, it is necessary to use probiotics in the poultry diet, which positively affected the microstructural integrity of the intestine and the stability of the microbiota. O.M. Chechet *et al.* (2022) argued that the use of probiotic drugs in broiler chickens is a promising area for increasing poultry resistance and productivity, providing prevention of infectious diseases in poultry. Researchers also pointed out the positive effect of the synbiotic drug “Biomagn” on the productivity and quality of poultry meat, in particular, on its morphological structure.

When feeding broiler chickens vitamin supplements containing tocopherol acetate and ascorbic acid, as indicated by O.I. Vishchur *et al.* (2020), there was an improvement in lipid synthesis in the liver and their deposition in skeletal muscle, and the preservation of liver and muscle structure. M.A.M. Shaufi *et al.* (2023) and G.M. Suliman *et al.* (2023) noted a positive effect of probiotics and their combinations on the gut microbiota of broiler chickens and the structure of muscle tissue and internal organs that did not change. Z. Zhang *et al.* (2023) proved that a probiotic *Lactobacillus johnsonii* had therapeutic properties in various diseases of poultry, had a positive effect on their performance, structure of internal organs, intestines, and muscle tissue. S.L. Weimer *et al.* (2018) noted a positive effects of probiotic preparation and yeast *Saccharomyces cerevisiae* on the structure of internal organs of broiler chickens. S. Aslam *et al.* (2020) found that the use of probiotic drugs in the diet of broiler chickens not only increased productivity, but also mobilised all processes in the body at

the cellular level, improved the physical and chemical parameters of meat, and the structure of muscle tissue and slaughter products. R.N. Soomro *et al.* (2019) proved that the probiotic mixture “Protexin” as a growth stimulator of poultry increased productivity, improved health and reduced mortality rate for raising meat-type quails, and improved the qualitative and morphological parameters of muscle tissue and internal organs.

## Materials and Methods

The research was conducted in 2022-2023 in the accredited research laboratory of the Department of the Veterinary and Sanitary Expertise, Hygiene of Animal Husbandry Products and Pathological Anatomy called after J.S. Zahaiievskiy and accredited research laboratory of the Department of Veterinary and Sanitary Expertise of Institute of Postgraduated Education for managers and specialists of Veterinary medicine of the Bila Tserkva National Agrarian University.

Samples of the pectoralis major muscle of broiler chickens and internal organs of the bird – the heart, spleen, liver, the muscular part of the stomach and lungs – served as material for the study. A control group of broiler chickens was formed in the amount of 20 animals, who were not given probiotic biologics “Subtiform”, and three experimental groups (each with 20 animals) – who were given probiotic biologics with water as follows: chickens of the experimental group 1-0.5 g/10 dm<sup>3</sup>; experimental group 2-2.0 g/10 dm<sup>3</sup>; experimental group 3-4.0 g/10 dm<sup>3</sup>. The drug was given to broiler chickens from 28 to 42 days of rearing.

According to the methodology of L.P. Horalskyi *et al.* (2015) and the national standard DSTU 7353:2013 (2014) a microstructural analysis of the pectoralis major and internal organs (heart, spleen, liver, stomach muscles, and lungs) of broiler chickens was performed. At

least three pieces of the pectoralis major muscle and internal organs, 0.2-0.4 cm thick, were taken from each sample and placed in disposable labelled plastic cassettes, which were then placed in a container for fixation with a 10% aqueous formalin solution.

Subsequently, histological preparations were made from the selected material and stained with Carazzi's hematoxylin and eosin to identify the main structural elements of tissues and pathological changes. The histological specimens were microscoped using an Axioskop laboratory microscope (Poland) on a "light field" contrast at 10x, 20x, 40x magnification and a colour digital camera Industrial Digital Camera 8.OMP 1/2.5 Color USB 2.0 with a resolution of 8.0 MP (Poland), which reflected the actual magnification of the objects in the field of view. ToupView software was used to analyse the image. When stained with Carazzi's hematoxylin and eosin, the cell nuclei were stained blue-purple, the cytoplasm – pink-red. Microstructural analysis of the pectoralis major, heart, spleen, liver, stomach, and lung muscles was performed in accordance with the requirements of the regulatory document (DSTU 7353:2013, 2014).

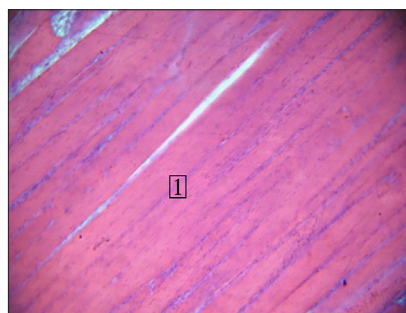
Scientific research was conducted in accordance with requirements of DSTU ISO/IEC 17025:2005 (2006), EUs Directive 2010/63/EU on the protection of animals used for scientific purposes (2010) and Law of Ukraine No. 3447-IV (2006, February).

## Results and Discussion

According to histological studies of the pectoralis major muscle and internal organs of broiler chickens: heart, spleen, liver, muscle part of the stomach and lungs, it was found that the microstructure of the pectoralis major muscle did not change, but revealed muscles consisting

of relatively large fibres, and others – of smaller fibres. The nuclei had an elongated-oval shape. In the striated muscles, the nuclei were located on the periphery of the cytoplasm, the fibers – near the sarcolemma and are oriented parallel to it by their long axis. Transverse straight stripes are visible on clearly longitudinal sections. But on sections that run slightly obliquely, these stripes are arched (Fig. 1-14).

Along the longitudinal section, the muscle fibres of the pectoralis major muscle of broiler chickens of the control group are the same thickness and evenly directed (Fig. 1).

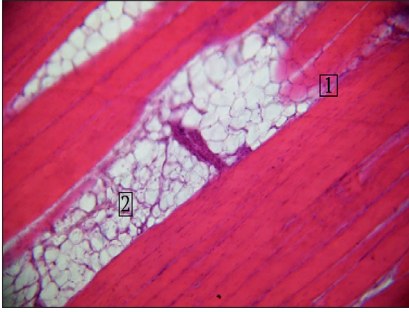


**Figure 1.** Morphologically unchanged structure of the muscle tissue of the pectoralis major muscle in the control group

**Notes:** 1 – muscle fibres are the same thickness, evenly directed. Staining with Carazzi's hematoxylin and eosin, x200

**Source:** developed by the authors

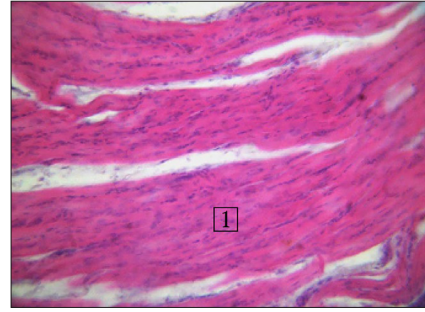
A uniform pale pink cytoplasm and empty blood vessels were noted. Rather large nuclei of elongated-oval shape, light, weakly basophilic, located closer to the sarcolemma containing nucleoli were observed. It was also noted that individual muscles had constrictions, which preceded their fragmentation. Minor fat layers were found between the bundles of muscle fibres (Fig. 2).



**Figure 2.** Morphologically unchanged structure of the muscle tissue of the pectoralis major muscle in the control group

**Notes:** 1 – constrictions in the muscles; 2 – fat layers. Staining with Carazzi's hematoxylin and eosin, x200

**Source:** developed by the authors



**Figure 3.** Microscopic structure of the heart muscle of broiler chickens from the control group

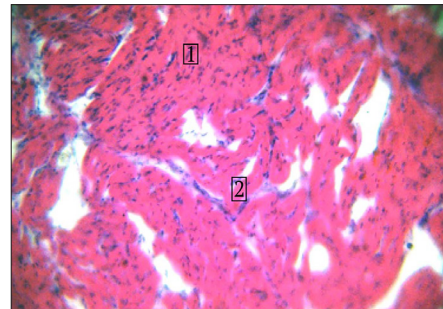
**Notes:** 1 – cardiomyocytes (in longitudinal section) are the same thickness. Staining with Carazzi's hematoxylin and eosin, x200

**Source:** developed by the authors

Figure 3 shows the microscopic structure of the heart muscle of broiler chickens in the control group. Morphologically unchanged structure of the heart muscle was noted. The heart muscle tissue looked like a mass of branching and anastomosing fibres separated by slit-like spaces. These fibres were made up of individual cells connected end-to-end. The slit-like spaces between the anastomosing fibres were filled by the endomysium, where capillaries and lymphatic vessels passed closely. The fibres of the heart muscle are characterised by transverse striation. Individual heart muscle fibre cells usually contained a single nucleus, but sometimes binucleated cells were also found. It was noted that the nuclei are slightly larger and lighter than in skeletal muscle fibres and are usually located closer to the central axis of the fibre.

Thus, Figure 3 shows that the structure of the heart muscle is preserved: cardiomyocytes (in longitudinal section) are the same thickness, pale pink with homogeneous cytoplasm. The nuclei are cigar-shaped, basophilic, with a moderate chromatin content. The vessels are moderately dilated and thickened.

From the cross-section of the muscles, a uniform pale pink cytoplasm was noted, the nuclei in which are moderately basophilic. The vessels are moderately dilated (Fig. 4).



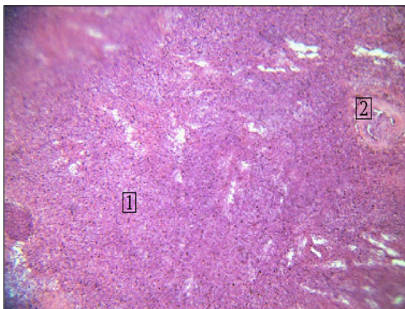
**Figure 4.** Microscopic structure of the heart muscle of broiler chickens from the control group

**Notes:** 1 – in a cross-section of the muscle – the structure is preserved, the cytoplasm is uniformly pale pink; 2 – vessels are moderately dilated. Staining with Carazzi's hematoxylin and eosin, x200

**Source:** developed by the authors

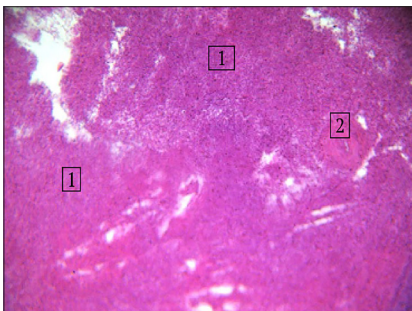
Histological examination of the spleen of broiler chickens from the control group revealed that the structure of the organ is represented

by a diffuse accumulation of leukocytes at varying stages of differentiation. The vessels are desolate and moderately dilated (Fig. 5).



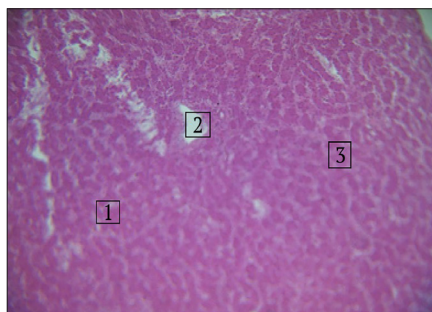
**Figure 5.** Microscopic structure of the spleen of broiler chickens from the control group  
*Notes:* 1 – diffuse accumulation of leukocytes; 2 – vessels are moderately dilated. Staining with Carazzi's hematoxylin and eosin, x200  
*Source:* developed by the authors

The trabecular base of the spleen is poorly defined (Fig. 6). Lymphoid nodules do not have a clear structure.



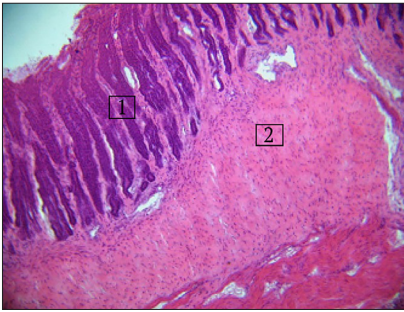
**Figure 6.** Microscopic structure of the spleen of broiler chickens from the control group  
*Notes:* 1 – leukocytes in a state of differentiation; 2 – vessel. Staining with Carazzi's hematoxylin and eosin, x200.  
*Source:* developed by the authors

According to the conducted studies, it was found that the morphological structure of the liver of broiler chickens of the control group did not undergo pathological changes. The liver lobules are usually separated from each other by layers of loose connective tissue called interlobular septa or interstices. In the liver of broiler chickens, interparticle layers were not visible. Figure 7, 1 show that hepatocytes are collected in groups of the same type. The central veins are desolate (Fig. 7, 2), of moderate size. The cytoplasm of hepatocytes is uniform, clear, and pink. The nuclei are weakly basophilic. Interstitial vessels are desolate (Fig. 7, 3) or contain isolated blood cells.



**Figure 7.** Microstructure of liver hepatocytes in broiler chickens from the control group  
*Notes:* 1 – hepatocytes; 2 – central vein is desolate; 3 – interstitial vessels are desolate. Staining with Carazzi's hematoxylin and eosin, x200  
*Source:* developed by the authors

Histological examination of the muscular part of the stomach of broiler chickens was observed (Fig. 8) that the cuticle is represented by a formed epithelial layer (Fig. 8, 1) under which a sufficiently wide layer is occupied by the connective tissue base.

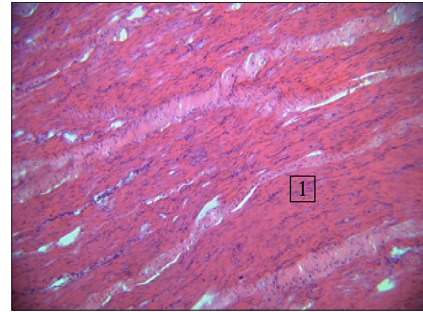


**Figure 8.** Formed epithelial layer of the muscle cuticle parts of the stomach of broiler chickens from the control group

**Notes:** 1 – epithelial layer; 2 – submucosal base. Staining with Carazzi's hematoxylin and eosin, x200

**Source:** developed by the authors

Under the stromal base there are muscle fibres that are loosened by rather voluminous layers of the mesenchyme (Fig. 9, 1). The vessels are dilated, partially filled with blood cells (Fig. 9; 10).

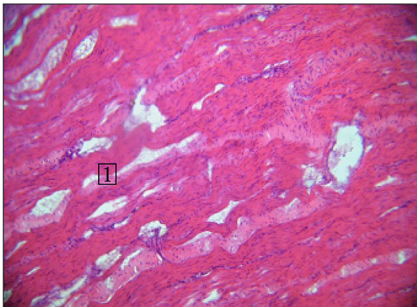


**Figure 10.** Microscopic structure of the muscular part of the stomach of broiler chickens from the control group

**Notes:** 1 –longitudinal section of the muscles. Staining with Carazzi's hematoxylin and eosin, x200

**Source:** developed by the authors

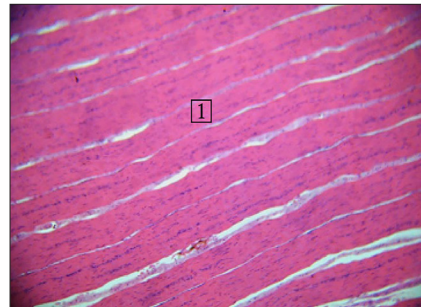
The lower layers of muscles (relative to the cuticle) are characterised by uniformity, clear orientation (Fig. 11, 1). The nuclei are elongated-oval in shape and moderately basophilic (Fig. 11).



**Figure 9.** Microscopic structure of the muscular part of the stomach of broiler chickens of broiler chickens from the control group

**Notes:** 1 – loose muscle fibres. Staining with Carazzi's hematoxylin and eosin, x200

**Source:** developed by the authors

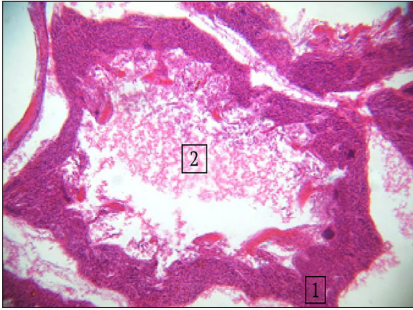


**Figure 11.** Microscopic structure of the muscular part of the stomach of broiler chickens from the control group

**Notes:** 1 – longitudinal direction of muscle fibres. Staining with Carazzi's hematoxylin and eosin, x200

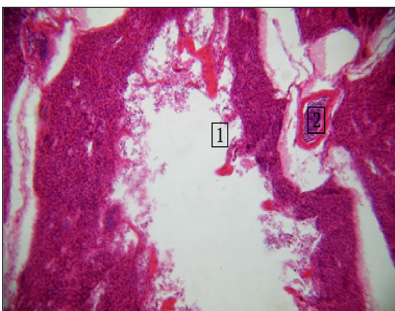
**Source:** developed by the authors

Histological examination of the lungs of broiler chickens revealed that the bronchial tubes largely contained blood cells (possibly post-slaughter artefacts) (Fig. 12).



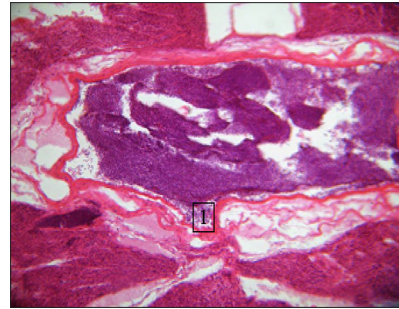
**Figure 12.** Microscopic structure of the lungs of broiler chicken from the control group  
*Notes:* 1 – bronchial tubes; 2 – shaped elements. Carazzi's hematoxylin and eosin, x200  
*Source:* developed by the authors

The structure of the lung tissue was in a state of compression deformation (Fig. 13).



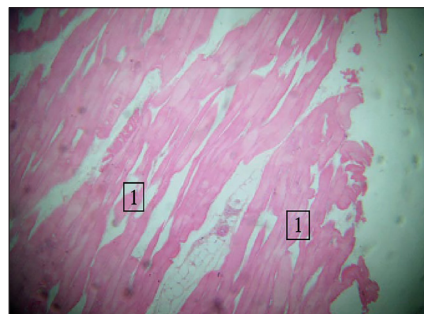
**Figure 13.** Compression deformity in the lungs of broiler chicken from the control group  
*Notes:* 1 – deformed wall of the bronchial tube; 2 – a vessel containing blood cells. Staining with Carazzi's hematoxylin and eosin, x200.  
*Source:* developed by the author

The vessels of the organ contained a significant amount of blood cells (possibly poor exsanguination of the carcass) (Fig. 14, 1).

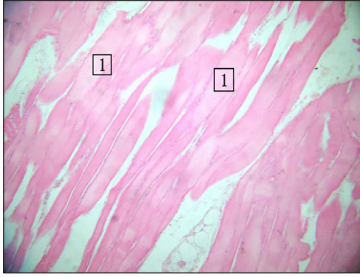


**Figure 14.** Microscopic structure of the lungs of broiler chicken from the control group  
*Notes:* 1 – blood cells in the vessels of the lungs. Staining with Carazzi's hematoxylin and eosin, x200  
*Source:* developed by the authors

Figures 15 and 16 show the microscopic structure of the pectoralis major muscle of broiler chickens from experimental group 1. It was found that according to the longitudinal projection, the pectoralis major muscles are uniform, striation was not determined, they have different thickness, single – minor flask-shaped thickenings. Most muscle groups are divided into fairly large fragments (Fig. 15, 1). The cytoplasm of muscle fibres is weakly eosinophilic and has different intensity. The nuclei, in most cases, are located closer to sarcolemes, elongated, of which single ones have acquired a rounded shape, weakly basophilic.



**Figure 15.** Pectoralis major of broiler chickens from experimental group 1  
*Notes:* 1 – muscle fragmentation. Staining with Carazzi's hematoxylin and eosin, x200  
*Source:* developed by the authors

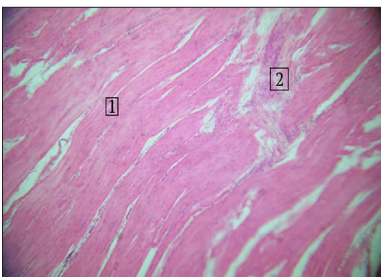


**Figure 16.** Pectoralis major of broiler chickens from experimental group 1

**Notes:** 1 – muscle cytoplasm is weakly basophilic. Staining with Carazzi's hematoxylin and eosin, x400

**Source:** developed by the authors

Figure 17 presents the preserved morphological architectonics of the heart (epicardium, myocardium, endocardium) of broiler chickens from experimental group 1. Cardiomyocytes, in longitudinal section, are homogeneous, had a clear direction, the latter anastomosed with each other, forming specific branched formations. Intermuscular connective tissue is moderately loose (Fig. 17, 2), along the course of the fibres, there are blood capillaries located in the endomysium. The cytoplasm of cardiomyocytes is pale pink, uniformly homogeneously coloured. The nuclei are elongated (cigar-shaped), moderately basophilic, and the vessels are desolate.

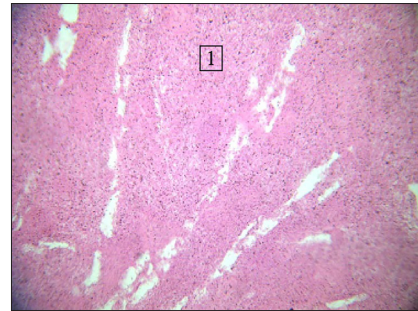


**Figure 17.** Microscopic structure of the heart muscle of broiler chickens from experimental group 1

**Notes:** 1 – bundles of muscle fibres; 2 – intermuscular connective tissue. Staining with Carazzi's hematoxylin and eosin, x200

**Source:** developed by the authors

According to histological examination of the spleen (Fig. 18) it was found that leukocytes are diffusely placed throughout the entire structure of the specimen under study (Fig. 18, 1) at different stages of differentiation. Lymphoid nodules are single, clearly defined. Vessels of various calibre, desolate. The trabecular base is poorly developed.



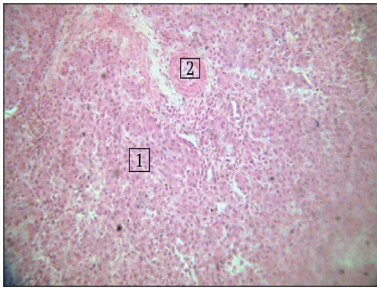
**Figure 18.** Microscopic structure of the spleen of broiler chickens from experimental group 1

**Notes:** 1 – diffuse placement of leukocytes. Staining with Carazzi's hematoxylin and eosin, x200

**Source:** developed by the authors

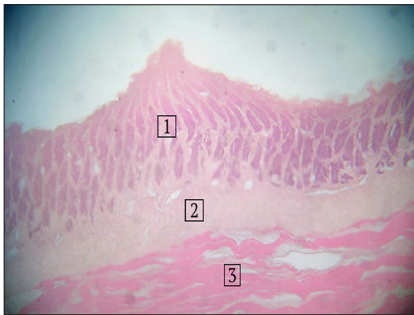
The liver microstructure of broiler chickens from experimental group 1 is represented by unformed groups of hepatocytes (Fig. 19). Hepatocytes are slightly enlarged and displaced relative to the basement membrane (Fig. 19, 1), contained clear eosinophilic cytoplasm of varying intensity. The nuclei of such hepatocytes are enlarged, the karyoplasm is clear. Interstitial vessels (Fig. 19, 2) and the central veins are desolate. The bile ducts are clearly developed. The latter do not have an exosecret.

Microscopic structure of the stomach of broiler chickens from experimental group 1 (Fig. 20) is represented by the developed epithelial layer of the cuticle (Fig. 20, 1) under which a sufficiently wide layer is occupied by a connective tissue base (Fig. 20, 2). Under the latter are muscle fibres (Fig. 20, 3), which are separated by rather voluminous layers of the mesenchyme.



**Figure 19.** Microscopic structure of the liver of broiler chickens from experimental group 1  
*Notes:* 1 – liver plates; 2 – vessel. Staining with Carazzi's hematoxylin and eosin, x400

*Source:* developed by the authors



**Figure 20.** Microscopic structure of the muscular part of the stomach of broiler chickens from experimental group 1

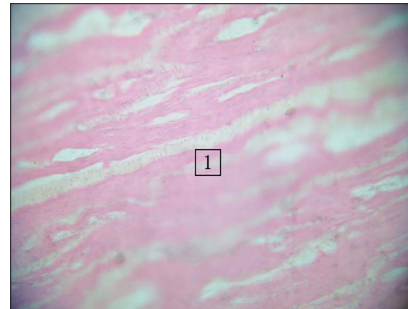
*Notes:* 1 – epithelial layer; 2 – submucosal base; 3 – muscles. Staining with Carazzi's hematoxylin and eosin, x200

*Source:* developed by the authors

The vessels are intensively dilated, partially filled with blood cells. Figure 21 shows that the muscle layers below (relative to the cuticle) are uniform and loose (Fig. 21, 1), have a certain orientation. The nuclei are elongated, moderately basophilic.

The structure of the lungs was characterised by the fact that the bronchial tubes (Fig. 22, 1) largely contain blood cells, possibly a post-slaughter artefact. The structure of lung tissue in a state of compression deformation.

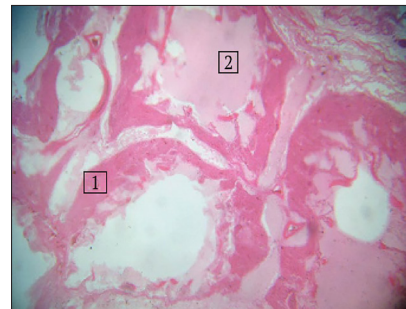
The vessels of the organ contain a significant amount of blood cells (poor exsanguination of the carcass is possible) (Fig. 22).



**Figure 21.** Microscopic structure of the muscular part of the stomach of broiler chickens from experimental group 1

*Notes:* 1 – loose muscle fibres. Staining with Carazzi's hematoxylin and eosin, x200

*Source:* developed by the authors

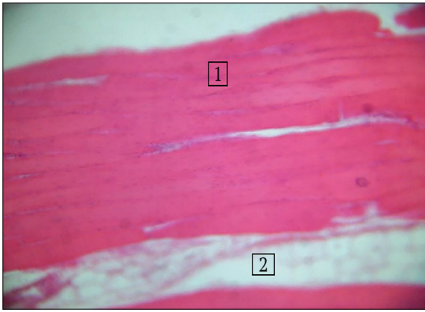


**Figure 22.** Microscopic structure of the lungs of broiler chickens from experimental group 1

*Notes:* 1 – bronchial tubes; 2 – hemolysed erythrocytes. Staining with Carazzi's hematoxylin and eosin, x200

*Source:* developed by the authors

Figure 23 shows the microscopic structure of the pectoralis major muscle of broiler chickens from experimental group 2 – part of the pectoralis major muscle is thickened (Fig. 23, 1), contained pale pink cytoplasm; the nuclei are weakly basophilic, elongated. Between the fragments of muscle fibres – layers of adipose tissue (Fig. 23, 2)

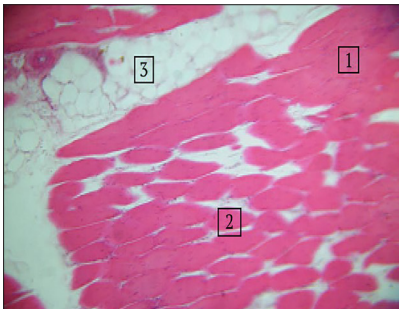


**Figure 23.** Microscopic structure of the pectoralis major muscle of broiler chickens from experimental group 2

**Notes:** 1 – muscle fibres; 2 – layers of adipose tissue. Staining with Carazzi's hematoxylin and eosin, x200

**Source:** developed by the authors

Thickened, partially fragmented muscle fibres of the pectoralis major (Fig. 24, 1) with a uniform pale pink cytoplasm, oval-elongated nuclei with a low chromatin content. Adipose tissue is placed between individual fragments of muscle fibres (Fig. 24, 3).



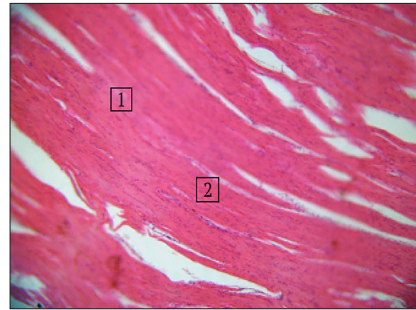
**Figure 24.** Microscopic structure of the pectoralis major muscle of broiler chickens from experimental group 2

**Notes:** 1 – muscle fibres; 2 – muscle fragmentation; 3 – adipose tissue. Staining with Carazzi's hematoxylin and eosin, x200

**Source:** developed by the authors

Figure 25 shows that the structure of the myocardium is preserved: cardiomyocytes (in longitudinal section) are of the same thickness,

have a pale pink cytoplasm of uniform density (Fig. 25, 1). The vessels are moderately dilated and desolate. According to the cross-section of the muscles, the structure is preserved (Fig. 25, 2), the cytoplasm is uniformly pale pink, the nuclei are moderately basophilic.

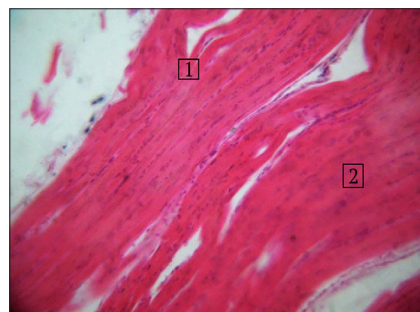


**Figure 25.** Microscopic structure of the heart muscle of broiler chickens from experimental group 2

**Notes:** 1 – cardiomyocytes; 2 – the muscle structure is preserved. Staining with Carazzi's hematoxylin and eosin, x200

**Source:** developed by the authors

Individual muscle fibres are clear and contain an enlarged, rounded nucleus with a low chromatin content (Fig. 26, 2).

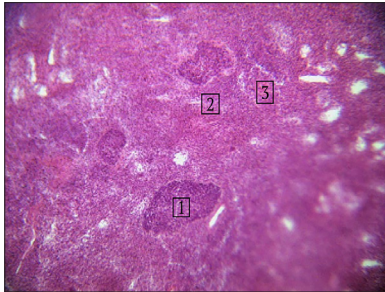


**Figure 26.** Microscopic structure of the heart muscle of broiler chickens from experimental group 2: preservation of muscle structure

**Notes:** 1 – clear muscle karyoplasm; 2 – muscle fibres. Staining with Carazzi's hematoxylin and eosin, x400

**Source:** developed by the authors

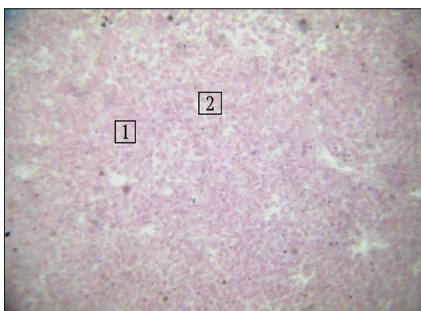
In the spleen, the white pulp was based on lymphoid nodules, and diffusely placed leukocytes were recorded at different stages of differentiation (Fig. 27).



**Figure 27.** Microscopic structure of the spleen of broiler chickens from experimental group 2  
**Notes:** 1 – lymphoid nodules; 2 – red pulp; 3 – blood vessels. Staining with Carazzi's hematoxylin and eosin, x200

**Source:** developed by the authors

Histological studies of the liver showed that the groups of hepatocytes are slightly enlarged with a uniform pale pink cytoplasm (Fig. 28, 1, 2). The nuclei of such hepatocytes are rounded and enlarged. They contained a small amount of chromatin (Fig. 28).

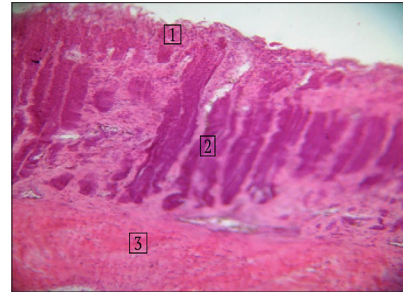


**Figure 28.** Follicular structure of the liver of broiler chickens from experimental group 2  
**Notes:** 1 – hepatocytes; 2 – hypochromic hepatocytes with clear cytoplasm. Staining with Carazzi's hematoxylin and eosin, x400

**Source:** developed by the authors

The apical part of the gastric cuticle of broiler chickens from experimental group 2 is

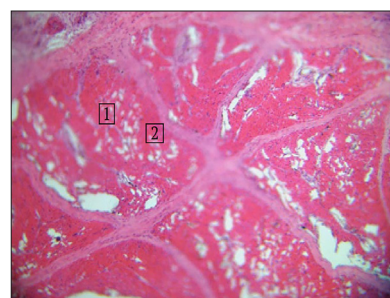
presented in a state of desquamation (peeling epithelium) (Fig. 29, 1). The cuticle is thinned (part of the epithelium is replaced by reticular cells and fibrous structures) (Fig. 29, 2).



**Figure 29.** Desquamation of the cuticle of the muscular part of the stomach of broiler chickens from experimental group 2  
**Notes:** 1 – cuticle desquamation; 2 – epithelium; 3 – submucosal base. Staining with Carazzi's hematoxylin and eosin, x200

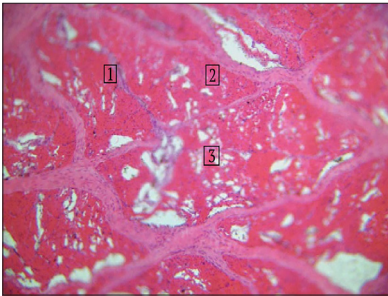
**Source:** developed by the authors

The muscles under the subquicular layer are clearly divided into bundles, and the muscle structure is somewhat blurred (some bundles are thicker, others are thinner), the intermuscular tissue is loosened. By the longitudinal section of the muscles – the latter are swollen, the structure is uniform, and the nuclei are mostly rounded, although they contain enough chromatin (Fig. 30; 31).



**Figure 30.** Microscopic structure of the muscular part of the stomach of broiler chickens from experimental group 2  
**Notes:** 1 – muscles; 2 – bundles of muscle fibres. Staining with Carazzi's hematoxylin and eosin, x200

**Source:** developed by the authors

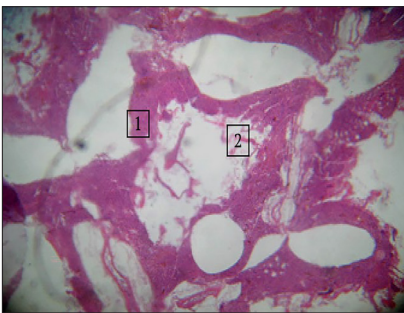


**Figure 31.** Microscopic structure of the muscular part of the stomach of broiler chickens from experimental group 2

**Notes:** 1 – muscles; 2 – bundles of muscle fibres; 3 – loosening of muscles. Staining with Carazzi's hematoxylin and eosin, x200

**Source:** developed by the authors

Figure 32 shows the microscopic structure of the lungs of broiler chickens from experimental group 2 in a state of compression deformation. The bronchial tubes largely contain blood cells (possibly a post-slaughter artefact). The vessels of the organ contain a significant amount of blood cells (poor exsanguination of the carcass is possible).



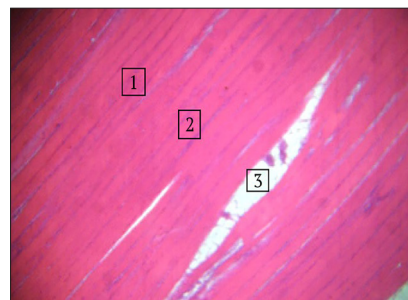
**Figure 32.** Compression deformity of the lung structure of broiler chickens from experimental group 2

**Notes:** 1 – bronchial tubes; 2 – compression deformation of the lung structure. Staining with Carazzi's hematoxylin and eosin, x200

**Source:** developed by the authors

Fig. 33, 34 show the microstructure of the pectoralis major muscle of broiler chickens from

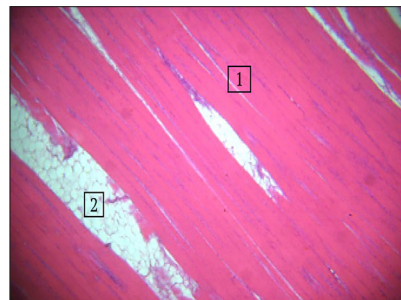
experimental group 3. According to the longitudinal section of the muscles, the following was recorded: muscle fibres of the same type, identical in thickness, evenly directed (Fig. 33, 1, 2). The vessels are desolate. The cytoplasm of muscle fibres is moderately eosinophilic, uniformly light pink. The nuclei are elongated-oval in shape, weakly basophilic, located closer to the sarcolemma, and contain nucleoli. Minor layers of adipose tissue were found between the bundles of muscle fibres (Fig. 33, 3).



**Figure 33.** Microstructure of the pectoralis major muscle of broiler chickens from experimental group 3

**Notes:** 1 – muscle; 2 – longitudinal muscle fibres; 3 – adipose tissue. Staining with Carazzi's hematoxylin and eosin, x200

**Source:** developed by the authors

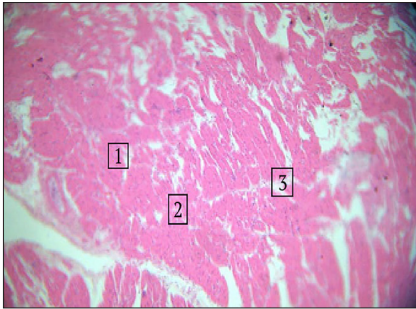


**Figure 34.** Microstructure of the pectoralis major muscle of broiler chickens from experimental group 3

**Notes:** 1 – longitudinal direction of muscle fibres; 2 – layers of fat. Staining with Carazzi's hematoxylin and eosin, x200

**Source:** developed by the authors

Figure 35 shows the microstructure of the heart muscle of broiler chickens from experimental group 3. It was found that the morphological architectonics of the heart were preserved, cardiomyocytes of longitudinal shape, uniform, clearly directed, anastomosed with each other, forming specific branched formations. Intermuscular connective tissue is moderately loose. Blood capillaries in the endomysium are located longitudinally, along the course of the fibres; the cytoplasm of cardiomyocytes is pale pink, uniformly coloured; the nuclei are elongated (cigar-shaped), moderately basophilic, the vessels are desolate.

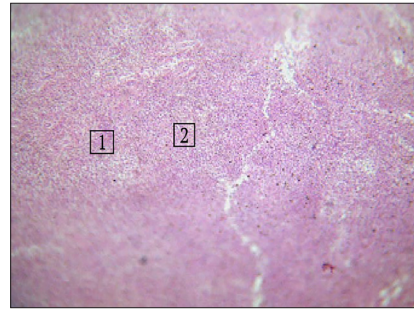


**Figure 35.** Morphological architectonics of the heart muscle broiler chickens from experimental group 3

**Notes:** 1 – cross-section of muscles; 2 – homogeneous eosinophilic karyoplasm; 3 – anastomoses of muscle fibres. Staining with Carazzi's hematoxylin and eosin, x200

**Source:** developed by the authors

Figure 36 shows the microstructure of the spleen of broiler chickens from experimental group 3. It was found that the follicular structure is formed with diffusely placed leukocytes at different stages of differentiation (Fig. 36, 2). A significant number of thickened vessels of various calibre were observed.

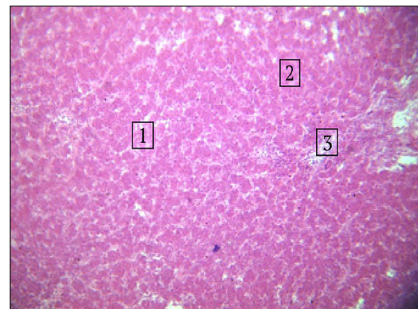


**Figure 36.** Microscopic structure of the spleen of broiler chickens from experimental group 3

**Notes:** 1 – homogeneous structure of red pulp; 2 – leukocytes in a state of differentiation. Staining with Carazzi's hematoxylin and eosin, x200

**Source:** developed by the authors

The microstructure of the liver is represented by hepatocytes collected in homogeneous groups (Fig. 37, 1). The central veins are desolate and moderate in size. The cytoplasm of hepatocytes is homogeneous, clear, and pink, their nuclei are weakly basophilic. The interstitial vessels were desolate or contained isolated blood cells.

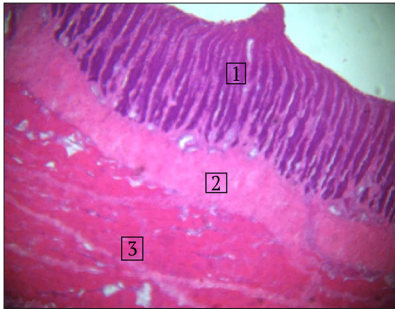


**Figure 37.** Uniformity of the microscopic structure of the liver of broiler chickens from experimental group 3

**Notes:** 1 – hepatocytes; 2 – preserved structure; 3 – central vein. Staining with Carazzi's hematoxylin and eosin, x200

**Source:** developed by the authors

Figure 38 shows the microscopic structure of the muscular part of the stomach of broiler chickens from experimental group 3.



**Figure 38.** Microscopic structure of the muscular part of the stomach of broiler chickens from experimental group 3

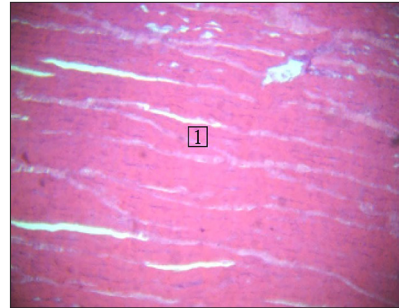
**Notes:** 1 – cuticle; 2 – connective tissue base; 3 – homogeneous muscles. Staining with Carazzi's hematoxylin and eosin, x200

**Source:** developed by the authors

The cuticle of the muscular part of the stomach of broiler chickens contained a formed epithelial layer (Fig. 38, 1) under which a sufficiently voluminous part of the connective tissue base layer is placed (Fig. 38, 2). Both layers of the muscular part of the stomach of broiler chickens form single, well-defined folds. Under the mesenchymal base of the cuticle are muscle fibres, which in some places are loosened by insignificant layers of the stroma. The vessels are dilated, partially filled with blood cells. Below (relative to the cuticle), the muscle layers are uniform and have a certain orientation. The nuclei are elongated-oval in shape, moderately basophilic (Fig. 39).

The microscopic structure of the lungs of broiler chickens from experimental group 3 is shown in Figures 40, 41. The bronchial tubes of the lungs contain blood cells, possibly as a

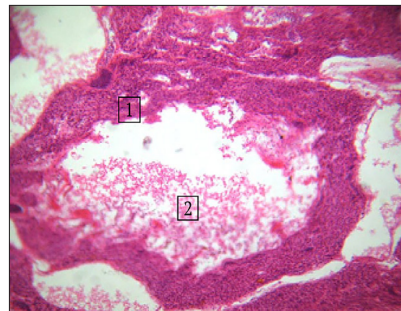
post-slaughter artefact (Fig. 40; 41, 1). The vessels of the organ contained a significant amount of blood cells (possibly poor exsanguination of the carcass) (Fig. 40, 2).



**Figure 39.** Uniformity of the microscopic structure of the muscle part of the stomach of broiler chickens from experimental group 3

**Notes:** 1 – longitudinal muscle section. Staining with Carazzi's hematoxylin and eosin, x200

**Source:** developed by the authors

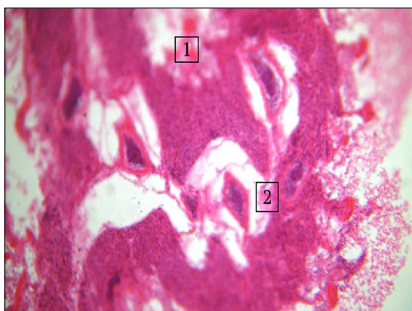


**Figure 40.** Microscopic structure of the lungs of broiler chicken from experimental group 3

**Notes:** 1 – bronchial tubes of the lungs; 2 – blood cells. Staining with Carazzi's hematoxylin and eosin, x200

**Source:** developed by the authors

The structure of the lung tissue was in a state of compression deformation (Fig. 41, 2).



**Figure 41.** Microscopic structure of the lungs of broiler chicken from experimental group 3

**Notes:** 1 – bronchial tubes of the lungs; 2 – structure of the lungs in a state of compression deformation. Staining with Carazzi's hematoxylin and eosin, x200

**Source:** developed by the authors

Researchers M. Angelovičová *et al.* (2016) argue that due to the use of phytogetic additives and nutraceuticals in feeding broiler chickens, the chemical composition of the pectoralis major and femoral muscles of carcasses improved. In particular, a significant increase in protein content by 3.05% ( $P < 0.001$ ) and fat content by 2.9% ( $P < 0.001$ ) was observed in the meat of this bird, which positively affected the morphological parameters of muscle tissue. The researchers did not note pathological changes in the form of granular dystrophy in the muscle tissue of broiler chickens and degeneration of internal organ tissues. In general, based on the conducted histological studies, they noted a positive effect of phytogetic additives and nutraceuticals on the development of internal organs of broiler chickens. Thus, the structure of the heart muscle was preserved. Cardiomyocytes had the same thickness, pale pink colour with uniform cytoplasm, basophilic nuclei with moderate chromatin content, slightly dilated and thickened vessels. In the muscular part of the stomach, the cuticle was represented by a developed epithelial layer, below which a significant layer of connective tissue base was

found. No pathological changes were detected in the liver, namely: the hepatic lobules of the gland were separated from each other by layers of connective tissue, including no interparticle layers. The structure of the spleen was marked by a diffuse accumulation of leukocytes at different stages of differentiation. Thus, the data of researchers correlated with the results obtained experimentally, according to Fig. 35-39.

The results obtained from this study coincide with the results of V.G. Stoyanovskyy *et al.* (2020), who found that when the probiotic “Laktin” was added to the diet with plant-based preparations, the morphological structure of the pectoralis major muscle of broiler chickens was characterised by the same type of muscle fibres, uniform orientation and looseness of the intermuscular connective tissue, which contained layers of adipose tissue. These morphological parameters corresponded to the author's results of experimental tests in the control group (Fig. 1, 2) and experimental groups of broiler chickens: 1 – Fig. 15, 16; 2 – Fig. 23, 24; 3 – Fig. 33, 34. The researchers also established a morphologically unchanged structure of the heart muscle, the same size of cardiomyocytes with a uniform pink cytoplasm and basophilic nuclei. Histological examination of the liver revealed that the hepatocytes were gathered in similar groups, the interstitial vessels and central veins were desolate, and in some places single blood cells were found, which confirmed the results of the tests with the probiotic. Thus, Figure 7, 1 shows that hepatocytes in the liver are collected in the same type of groups, the central veins are desolate (Fig. 7, 2) and of moderate size. The cytoplasm of hepatocytes is homogeneous, clear, and pink, the nuclei are weakly basophilic, the interstitial vessels are desolate. The vessels of the lung tissue contained a significant amount of blood cells, which indicated non-compliance with veterinary and sanitary requirements

when slaughtering broiler chickens and, as a result, poor exsanguination of poultry carcasses. According to the results of the study, similar data were obtained, in particular, a significant number of blood cells were found in the vessels of the organ, which may be due to poor exsanguination of the carcass (Fig. 14,1; 22; 32; 40). The structure of the lung tissue was in a state of compression deformation (Fig. 41, 2), which is also confirmed by researchers.

As noted by G. Vinderola *et al.* (2023), the use of probiotic drugs in the poultry diet had a positive effect on the morphological structure of the muscle tissue of the pectoralis major, femoral and cardiac muscles, and desolate vessels were also detected in the structure of the spleen. It was found that in the structure of the spleen of the control group of birds, the vessels are desolate and moderately dilated, the trabecular base of the spleen is poorly developed (Fig. 6). Figure 36 shows the uniformity of the red pulp structure in the spleen of the experimental group 3 of broiler chickens (Fig. 36, 1) and leukocytes in a state of differentiation (Fig. 36, 2).

But the microstructure of the liver did not change, but the interstitial vessels contained a small amount of blood cells. The researchers found that the microstructure of the muscular part of the stomach for the use of probiotic drugs in broiler chickens is represented by the formed epithelial layer of the cuticle, a wide layer of intermuscular connective tissue without pathological changes, which coincides with the results obtained in this study. J. Choi *et al.* (2023) indicated that probiotic drugs had a fairly positive effect on the development of the pectoralis major muscle of broiler chickens in the intermuscular connective tissue of which small layers of adipose tissue with muscle fibres of the same size were found. No pathological changes were detected in the heart muscle, and microstructural analysis of the lungs revealed that the bronchial tubes contained blood cells.

These data are also confirmed by the study – there are 3 broiler chickens in the experimental group, as shown in Figures 40; 41, 1, blood cells were found in the bronchial tubes of the lungs (possibly a post-slaughter artefact). Moreover, the vessels of the organ contained a significant amount of blood cells, probably due to poor exsanguination of the carcass (Fig. 40, 2). Researchers have noted that in the cross-section of the spleen, there were no small accumulations of leukocytes, and the microstructure of the liver remained unchanged.

The results of the study presented in this paper are also consistent with the results obtained by Y. Zhao *et al.* (2020), who claimed that when feeding broiler chickens a dietary probiotic *Bacillus licheniformis* H2 an increase in poultry productivity, improved immune status, and also had a positive effect on the microstructure of skeletal muscles and other internal organs, in particular the liver, heart muscle, and lungs, were observed. T. Yang *et al.* (2023) proved that the addition of probiotic drugs to the diet of broiler chickens led to rational digestion of feed and improved nutrient absorption. In turn, this affected the improvement of the quality indicators of meat and offal – an increase in water content by 2.9% ( $P < 0.001$ ), fat by 3.2% ( $P < 0.001$ ), protein by 3.2% ( $P < 0.001$ ), and their micromorphological characteristics – the development of the pectoralis major muscle with layers of adipose tissue, which is consistent with the results of microstructural analysis described in this paper (Fig. 34, 1; 34, 2); in the liver, hepatocytes were collected in groups of the same type, their cytoplasm looked uniform, clear and pink, the nuclei had weak basophilicity and empty interstitial vessels, which correlates with the data of this study (Fig. 37, 1; 37, 2); the spleen also had empty blood vessels, and its trabecular base looked underdeveloped, as shown in Fig. 36, 1; 36, 2; the bronchial tubes of the lungs contained blood cells, as shown

in Fig. 40, 1, 40, 2; the muscular part of the stomach was well developed, had a sufficiently formed epithelial layer and a voluminous layer of connective tissue base, which corresponded to the results of this study (Fig. 38, 1; 38, 2).

To achieve an optimal effect, it is necessary to make a choice in favour of probiotic strains of microorganisms *Bacillus subtilis* and *Bacillus licheniformis*. J. Karavolias *et al.* (2018) noted that the national policy of most European countries is aimed at growing animals and poultry are free of antibiotics, and therefore, the use of probiotics is an alternative in animal husbandry, in particular in poultry farming. Researchers claimed a pronounced positive effect of probiotics on the well-being of broiler chickens, preventing the occurrence of infectious diseases, and improving the safety and quality of slaughter products.

A. Sharma *et al.* (2019) emphasised that, guided by European regulations, in particular Regulation of the European Union No. 625 (2017), veterinary inspectors should identify the risks associated with production, in particular, the inclusion of probiotic drugs in the poultry diet that affect their health and productivity, and control the circulation of meat and slaughter products of broiler chickens. For the implementation of the traceability system, which is an integral part of the functioning of the HACCP system, at the poultry meat production facility, it is necessary to follow the basic requirements for establishing dangerous risks at all stages of production and sale of broiler chicken slaughter products in accordance with the requirements of Regulation of the European Union No. 765 (2008).

The Rapid Alert System for Food and Feed (RASFF) has provided the competent control authorities with an effective tool for exchanging information on sanitary and hygienic measures to ensure the safety of feed and feed additives that have affected the safety of broiler chicken

slaughter products in accordance with the requirements of the regulatory document Regulation of the European Union No. 1020 (2019). The results obtained were consistent with the requirements of this document. Thus, having studied the effect of the probiotic “Subtiform” in different doses on the microstructure of the pectoralis major muscle and internal organs of broiler chickens, certain structural and morphological differences were found in the organs, which led to the following conclusions.

### Conclusions

According to microstructural changes in the pectoralis major muscle and internal organs (heart, spleen, liver, stomach muscle, lungs) of broiler chickens, the most favourable effect of the probiotic biological product at a dose of 4.0 g/10 dm<sup>3</sup> of water was found (experimental group 3). The microscopic structure of the pectoralis major muscle of broiler chickens did not change, in particular, the muscle fibres did not differ in thickness, they were evenly directed, the cytoplasm was uniformly pale pink and fat layers were visible; the intermuscular connective tissue was somewhat loosened, and the blood capillaries in the endomysium followed the fibres. The structure of the heart muscle has been preserved, its cytoplasm is uniformly pale pink, the nuclei are moderately basophilic, cardiomyocytes in the longitudinal section are of the same size, and the vessels are desolate. Histological examination of the spleen revealed that the microstructure of the organ is represented by a diffuse accumulation of leukocytes at different stages of differentiation. At the same time, thickened vessels of various calibres were found in significant quantities. It was also proved that the microstructure of the liver of broiler chickens did not change after feeding the probiotic biological product “Subtiform”. It was found that the hepatocytes were gathered in groups of the same type, the

central veins and interstitial vessels were desolate or contained single blood cells. The microstructure of the muscular part of the stomach of broiler chickens is formed by the epithelial layer of the cuticle, under which a fairly wide layer of connective tissue base is placed, forming single, clearly formed folds. The vessels are dilated, slightly filled with blood cells, muscle fibres are located under the mesenchymal base of the cuticle, which are somewhat loosened by insignificant stroma layers. Histological examination of the lungs of broiler chickens revealed that the bronchial tubes of the lungs contain blood cells. The structure of the lung tissue is in a state of compression deformation, the vessels of the organ contain a significant amount of

blood cells (poor exsanguination of the carcass is possible). It is suggested that histological examination is an important method for identifying possible pathological changes in the organs of broiler chickens, which can lead to a decrease in their productivity, product quality, and associated risks. In the future study, it is planned to conduct microbiological tests of broiler chicken slaughter products with the use of a probiotic biological product.

### Acknowledgements

None.

### Conflict of Interest

None.

### References

- [1] Abdulkhaliq, F., & Sabow, A.D. (2023). Carcass characteristics and meat quality assessments in broiler chickens subject to different pre-slaughter restraining methods. *Tikrit Journal for Agricultural Sciences*, 23(2), 42-61. [doi: 10.25130/tjas.23.2.4](https://doi.org/10.25130/tjas.23.2.4).
- [2] Angelovičová, M., Mellen, M., Bučko, O., Tkáčová, J., Čapla, J., Zajác, P., & Angelovič, M. (2016). Relation between selected nutrients in the chicken meat depending on phytogetic feed additives. *Potravinarstvo Slovak Journal of Food Sciences*, 10(1), 215-222. [doi: 10.5219/573](https://doi.org/10.5219/573).
- [3] Arain, M.A., Nabi, F., Marghazani, I.B., & Hassan, F., Soomro, H., Kalhor, H., Soomro, F., & Buzdar, J.A. (2022). In ovo delivery of nutraceuticals improves health status and production performance of poultry birds: A review. *World's Poultry Science Journal*, 78(3), 765-788. [doi: 10.1080/00439339.2022.2091501](https://doi.org/10.1080/00439339.2022.2091501).
- [4] Aslam, S., Shukat, R., Khan, M.I., & Shahid, M. (2020). Effect of dietary supplementation of bioactive peptides on antioxidant potential of broiler breast meat and physicochemical characteristics of nuggets. *Food Science Animal Resource*, 40(1), 55-73. [doi: 10.5851/kosfa.2019.e82](https://doi.org/10.5851/kosfa.2019.e82).
- [5] Chechet, O.M., Kovalenko, V.L., Vishchur, O.I., Haidei, O.S., Liniichuk, N.V., Gutyj, B.V., & Krushelnytska, O.V. (2022). The activity of T- and B-cell links of specific protection of chicken-broilers under the influence of synbiotic preparation "Biomagn" and "Diolide" disinfectant. *Ukrainian Journal of Veterinary and Agricultural Sciences*, 5(1), 46-52. [doi: 10.32718/ujvas5-1.08](https://doi.org/10.32718/ujvas5-1.08).
- [6] Choi, J., Kong, B., Bowker, B.C., Zhuang, H., & Kim, W.K. (2023). Nutritional strategies to improve meat quality and composition in the challenging conditions of broiler production: A review. *Animals*, 13(8), article number 1386. [doi: 10.3390/ani13081386](https://doi.org/10.3390/ani13081386).
- [7] DSTU 7353:2013. (2014). "Meat. Methodology of histological determination of freshness and degree of ripening". Retrieved from [https://online.budstandart.com/ua/catalog/doc-page?id\\_doc=89373](https://online.budstandart.com/ua/catalog/doc-page?id_doc=89373).

- [8] DSTU ISO/IEC 17025:2006. (2006). *General requirements for the competence of testing and calibration laboratories*. Retrieved from [http://online.budstandart.com/ua/catalog/doc-page.html?id\\_doc=50873](http://online.budstandart.com/ua/catalog/doc-page.html?id_doc=50873).
- [9] EUs Directive 2010/63/EU on the protection of animals used for scientific purposes. (2010). Retrieved from <https://norecopa.no/legislation/eu-directive-201063/>.
- [10] George, A.S., & George, A.S.H. (2023). Optimizing poultry production through advanced monitoring and control systems. *Partners Universal International Innovation Journal (PUIJ)*, 1(5), 77-97. doi: 10.5281/zenodo.10050352.
- [11] Horalskyi, L.P., Khomych, V.T., & Kononskyi, O.I. (2015). *Fundamentals of histological technique and morphofunctional research methods in normal and pathological conditions: A study guide*. Zhytomyr: Polissya.
- [12] Jha, R., Singh, A.K., Yadav, S., Berrocoso, J.F.D., & Mishra, B. (2019). Early nutrition programming (*in ovo* and post-hatch feeding) as a strategy to modulate gut health of poultry. *Frontiers in Veterinary Science*, 6, article number 82. doi: 10.3389/fvets.2019.00082.
- [13] Karavolias, J., Salois, M.J., Baker, K.T., & Watkins, K. (2018). Raised without antibiotics: Impact on animal welfare and implications for food policy. *Animal Science*, 2(4), 337-348. doi: 10.1093/tas/txy016.
- [14] Kler, R., Gangurde, R., Elmiraev, S., Hossain, M.S., Vo, N.V., Nguyen, T.V., & Kumar, P.N. (2022). Optimization of meat and poultry farm inventory stock using data analytics for green supply chain network. *Hindawi Discrete Dynamics in Nature and Society*, 2022, article number 8970549. doi: 10.1155/2022/8970549.
- [15] Law of Ukraine No. 3447-IV “On Protection of Animals from Cruelty”. (2006, February). Retrieved from <https://zakon.rada.gov.ua/laws/show/3447-15#Text>.
- [16] Lei, J., Dong, Y., Hou, Q., He, Y., Lai, Y., Liao, C., Kawamura, Y., Li, J., & Zhang, B. (2022). Intestinal microbiota regulate certain meat quality parameters in chicken. *Frontiers in Nutrition*, 9, article number 747705. doi: 10.3389/fnut.2022.747705.
- [17] Memon, F.U., Yang, Y., Zhang, G., Leghari, I.H., Lv, F., Wang, Y., Laghari, F., Khushk, F.A., & Si, H. (2022). Chicken gut microbiota responses to dietary *Bacillus subtilis* probiotic in the presence and absence of *Eimeria* infection. *Microorganisms*, 10(8), article number 1548. doi: 10.3390/microorganisms10081548.
- [18] Paliy, A.P., Stegnyy, B.T., Paliy, A.P., Rodionova, A.O., Bogatko, N.M., Vashchuk, Ye.V., Sakhniuk, N.I., Ovcharenko, H.V., Dudus, T.V., Ihnatieva, T.M., & Kovalenko, L.V. (2020). Microstructural analysis of sausage quality. *Ukrainian Journal of Ecology*, 10(2), 404-409. doi: 10.15421/2020\_115.
- [19] Regulation (EU) 2019/1020 of the European Parliament and of the Council of 20 June 2019 “On Market Surveillance and Compliance of Products and Amending Directive 2004/42/EC and Regulations (EC) No. 765/2008 and (EU) No. 305/2011”. (2019, June). Retrieved from <https://eur-lex.europa.eu/legal-content/EN/TXT/?uri=celex:32019R1020>.
- [20] Regulation (EU) 2019/1020 of the European Parliament and of the Council of 20 June 2019 “On Market Surveillance and Compliance of Products and Amending Directive 2004/42/EC and Regulations (EC) No. 765/2008 and (EU) No. 305/2011”. (2019, June). Retrieved from <https://eur-lex.europa.eu/legal-content/EN/TXT/?uri=celex:32019R1020>.

- [21] Regulation of the European Parliament and of the Council (EU) No. 765/2008 “On the Establishment of Requirements for Accreditation and Market Surveillance Related to the Sale of Products and on the Repeal of Regulation (EEC) No. 339/93. (2008, July). Retrieved from [https://zakon.rada.gov.ua/laws/show/994\\_938#Text](https://zakon.rada.gov.ua/laws/show/994_938#Text).
- [22] Regulation of the European Parliament and of the Council (EU) No. 1381/2019 “Regarding the Transparency and Sustainability of Risk Assessment in the Food Chain”. (2019, June). Retrieved from [https://zakon.rada.gov.ua/laws/show/984\\_032-09#Text](https://zakon.rada.gov.ua/laws/show/984_032-09#Text).
- [23] Rousseaux, A., Brosseau, C., & Bodinier, M. (2023). Immunomodulation of B- lymphocytes by prebiotics, probiotics and synbiotics: Application in pathologies. *Nutrients*, 15(2), article number 269. doi: 10.3390/nu15020269.
- [24] Shalginbayev, D., Uazhanova, R., & Mateyeva, A. (2022). Development of a laboratory method for determination of the quality and freshness of frozen poultry meat. *Potravinarstvo Slovak Journal of Food Sciences*, 16, 271-278. doi: 10.5219/1757.
- [25] Sharma, A., Motta, V., & Martinez, L. (2019). Effectiveness of short videos to enhance HACCP information for consumers. *Journal of Foodservice Business Research*, 22(1), 1-14. doi: 10.1080/15378020.2019.1663104.
- [26] Shaufi, M.A.M., Sieo, C.C., Chong, C.W., Geok Hun, T., Omar, A.R., Han Ming, G., & Wan Ho, Y. (2023). Effects of phage cocktail, probiotics, and their combination on growth performance and gut microbiota of broiler chickens. *Animals*, 13(8), article number 1328. doi: 10.3390/ani13081328.
- [27] Soomro, R.N., Abd El-Hack, M.E., Shah, S.S., Taha, A.E., Alagawany, M., Swelum, A.A., Hussein, E.O.S., Ba-Aawadh, H.A., Saadeldin, I., El-Edel, M.A., & Tufarelli, V. (2019). Impact of restricting feed and probiotic supplementation on growth performance, mortality and carcass traits of meat-type quails. *Animal Science*, 90(10), 1388-1395. doi: 10.1111/asj.13290.
- [28] Stoyanovskyy, V.G., Shevchuk, M.O., & Kolomiets, I. A. (2020). Physiological state of the body of broiler chickens against the background of combined stress when humic acids and probiotics are included in the diet. *Scientific Bulletin of the Lviv National University of Veterinary Medicine and Biotechnology named after S.Z. Gzhitskyi (Veterinary Sciences)*, 22(99), 157-161. doi: 10.32718/nvvet9725.
- [29] Suliman, G.M., Hussein, E.O.S., Alsagan, A., Al-Owaimer, A.N., Alhotan, R., Al-Baadani, H.H., Ba-Awadh, H.A., Qaid, M.M., & Swelum, A.A. (2023). Effects of adding nano-emulsified plant oil and probiotics to drinking water during different periods besides sex on processing characteristics, physicochemical properties, and meat quality traits of broiler chickens. *Frontiers in Veterinary Science*, 10, article number 1133605. doi: 10.3389/fvets.2023.1133605.
- [30] Tavaniello, S., De Marzo, D., Bednarczyk, M., Palazzo, M., Zejnelhoxha, S., Wu, M., Peng, M., Stadnicka, K., & Maiorano, G. (2023). Influence of a commercial synbiotic administered in ovo and in-water on broiler chicken performance and meat quality. *Foods*, 12(13), article number 2470. doi: 10.3390/foods12132470.
- [31] Vinderola, G., Cotter, P.D., Freitas, M., Gueimonde, M., Holscher, H.D., Ruas-Madiedo, P., Salminen, S., Swanson, K.S., Sanders, M.E., & Cifelli, C.J. (2023). Fermented foods: A perspective on their role in delivering biotics. *Frontiers in Microbiology*, 14, article number 1196239. doi: 10.3389/fmicb.2023.1196239.

- [32] Vishchur, O.I., Romanovych, L.V., Smolyaninov, K.B., Masyuk, M.B., & Romanovych, M.M. (2020). The effects of vitamins E and C on individual lipides in the liver and skeletal muscles of chicken broilers'. *Journal for Veterinary Medicine, Biotechnology and Biosafety*, 6(1), 11-14. [doi: 10.36016/JVMBBS-2020-6-1-2](https://doi.org/10.36016/JVMBBS-2020-6-1-2).
- [33] Weimer, S.L., Wideman, R.F., Scanes, C.G., Mauromoustakos, A., Christensen K.D., & Vizzier-Thaxton, Y. (2018). An evaluation of methods for measuring stress in broiler chickens. *Poultry Science*, 97(10), 3381-3389. [doi: 10.3382/ps/pey204](https://doi.org/10.3382/ps/pey204).
- [34] Yang, T., Du, M., Zhang, J., Ahmad, B., Cheng, Q., Wang, X., Abbas, Z., Tong, Y., Li, J., Zhou, Y., Zhang, R., & Si, D. (2023). Effects of *Clostridium butyricum* as an antibiotic alternative on growth performance, intestinal morphology, serum biochemical response, and immunity of broilers. *Antibiotics*, 12(3), article number 433. [doi: 10.3390/antibiotics12030433](https://doi.org/10.3390/antibiotics12030433).
- [35] Zhang, Z., Zhao, L., Wu, J., Pan, Y., Zhao, G., Li, Z., & Zhang, L. (2023). The effects of *Lactobacillus johnsonii* on diseases and its potential applications. *Microorganisms*, 11(10), article number 2580. [doi: 10.3390/microorganisms11102580](https://doi.org/10.3390/microorganisms11102580).
- [36] Zhao, Y., Zeng, D., Wang, H., Qing, X., Sun, N., Xin, J., Luo, M., Khalique, A., Pan, K., Shu, G., Jing, B., & Ni, X. (2020). Dietary probiotic *Bacillus licheniformis* H2 enhanced growth performance, morphology of small intestine and liver, and antioxidant capacity of broiler chickens against *Clostridium perfringens*-induced subclinical necrotic enteritis. *Probiotics and Antimicrobial Proteins*, 12(3), 883-895. [doi: 10.1007/s12602-019-09597-8](https://doi.org/10.1007/s12602-019-09597-8).
- [37] Zhu, Q., Sun, P., Zhang, B., Kong, L., Xiao, C., & Song, Z. (2021). Progress on gut health maintenance and antibiotic alternatives in broiler chicken production. *Frontiers in Nutrition*, 8, article number 692839. [doi: 10.3389/fnut.2021.692839](https://doi.org/10.3389/fnut.2021.692839).

## Мікроструктурний аналіз м'яса та внутрішніх органів курчат-бройлерів за використання пробіотичного біопрепарату

**Альона Федорівна Богатко**

Аспірант

Білоцерківський національний аграрний університет  
09117, Соборна площа, 8/1, м. Біла Церква, Україна  
<https://orcid.org/0000-0001-8089-5884>

**Микола Валентинович Утеченко**

Кандидат ветеринарних наук, доцент

Білоцерківський національний аграрний університет  
09117, Соборна площа, 8/1, м. Біла Церква, Україна  
<https://orcid.org/0000-0003-3747-9054>

**Анотація.** Пробіотичний препарат із умістом бактерій роду *Bacillus subtilis* і *Bacillus licheniformis* застосовується при годівлі курчат-бройлерів для покращення перетравлення корму, засвоюваності поживних речовин, підвищення імунного статусу та продуктивності, а також для профілактики і лікування різноманітних хвороб птиці. Мета роботи – провести гістологічні дослідження продуктів забою курчат-бройлерів при застосуванні їм пробіотичного біопрепарату в дозах: 0,5 г, 2,0, і 4,0 г на 10 дм<sup>3</sup> води. Матеріал досліджували гістологічним методом. Встановлено, що м'язові волокна у великому грудному м'язі однотипові, рівномірно направлені, цитоплазма м'язових волокон помірно еозинофільна, однорідно-світло-рожева, між пучками м'язових волокон виявлено незначні прошарки жирової тканини. Морфологічна архітектоніка серцевого м'яза збережена, кардіоміоцити однорідні, мають чітку спрямованість. При цьому, незмінена мікроструктура печінки курчат-бройлерів: гепатоцити зібрані в однотипні групи; центральні вени запустілі; цитоплазма цих клітин однорідна, просвітлена, рожева, ядра слабо базифільні. У селезінці фолікулярна структура оформлена, дифузно розміщені лейкоцити на різних етапах диференціювання; судини у значній кількості, загустілі, різного калібру. Кутикула м'язової частини шлунка містить сформований епітеліальний шар, виявлена об'ємна частина прошарку сполучнотканинної основи; під мезенхімальною основою кутикули розташовані м'язові волокна. Легені за морфологічною структурою мають бронхіальні трубочки по всій структурі, які містять формені елементи крові. За результатами проведених досліджень встановлено сприятливий вплив пробіотичного біопрепарату в дозі 4,0 г/10 дм<sup>3</sup> води на морфологію великого грудного м'яза та внутрішніх органів курчат-бройлерів. Тому, пробіотик у дозі 4,0 г/10 дм<sup>3</sup> води під час випоювання курчат-бройлерів можна рекомендувати для підвищення продуктивності та отримання безпечних продуктів забою. Практична значимість отриманих результатів полягає у визначенні особливостей впливу випоювання птиці різних доз пробіотику на мікроструктуру продуктів її забою, що важливо для отримання найкращого ефекту від його застосування

**Ключові слова:** птиця; великий грудний м'яз; продукти забою; гістологічні дослідження; морфологія; пробіотик