



Features of lung organometry in domestic animals of the Mammalian class (*Mammalia*)

Leonid Horalskyi*

Doctor of Veterinary Sciences, Professor
Zhytomyr Ivan Franko State University
10002, 40 V. Berdychivska Str., Zhytomyr, Ukraine
<https://orcid.org/0000-0002-4251-614X>

Nataliia Hlukhova

Candidate for the Degree of Doctor of Philosophy
Polissia National University
10008, 7 Staryi Blvd., Zhytomyr, Ukraine
<https://orcid.org/0000-0002-4129-7889>

Ihor Sokulskyi

PhD in Veterinary Sciences, Associate Professor
Polissia National University
10008, 7 Staryi Blvd., Zhytomyr, Ukraine
<https://orcid.org/0000-0002-6237-0328>

Nataliia Kolesnik

PhD in Veterinary Sciences, Associate Professor
Polissia National University
10008, 7 Staryi Blvd., Zhytomyr, Ukraine
<https://orcid.org/0000-0001-7741-8753>

Irina Onyshchuk

PhD in Biological Sciences, Associate Professor
Zhytomyr Ivan Franko State University
10002, 40 V. Berdychivska Str., Zhytomyr, Ukraine
<https://orcid.org/0000-0002-2847-8570>

Suggested Citation:

Horalskyi, L., Hlukhova, N., Sokulskyi, I., Kolesnik, N., & Onyshchuk, I. (2023). Features of lung organometry in domestic animals of the Mammalian class (*Mammalia*). *Ukrainian Journal of Veterinary Sciences*, 14(1), 9-25. doi: 10.31548/veterinary1.2023.09.

*Corresponding author



Abstract. The study of the animal body and its morphoarchitectonics is a priority area for the successful development of animal husbandry. The purpose of the study is to establish the macroscopic structure of the lungs and provide an organometric assessment of their morphological structures in domestic sexually mature animals. The study used 30 clinically healthy individuals of 6 animal species belonging to the class *Mammalia* – Mammals. According to the results of the morphometry analysis of absolute and relative lung values in domestic mammals and their right and left lobes, a pronounced asymmetry was established, the coefficient of which corresponded to: in rabbits – 1:1.30, in dogs – 1:1.33, in sheep – 1:1.37, in pigs – 1:1.34, in cattle – 1:1.37, in horses – 1:1.2. For morphological assessment of typical lung features characteristic of a particular animal species, a morphological scale of marker features of the organ is proposed. According to the results of the study, it is proposed to classify the lungs of domestic mammals, considering the structure and shape, into 4 types: 1st – expanded-shortened (lung development index (LDI) = 85–100%); 2nd –intermediate (LDI = 101–120%); 3rd – moderately elongated (LDI = 121–130%); 4th – elongated (LDI = 131–140%). Based on a detailed analysis of organometric studies, a scale for assessing marker features of the lung is proposed – in rabbits (LDI = $90 \pm 1.89\%$) assigned to the extended-shortened type, in cattle (LDI = $117 \pm 2.21\%$) and sheep (LDI = $114 \pm 2.08\%$) – intermediate type, in horses (LDI = $127 \pm 2.74\%$) – moderately elongated type, in pigs (LDI = $136 \pm 3.01\%$) and dogs (LDI = $137 \pm 2.84\%$) – elongated type. The obtained results of morphological studies of the lungs of the representatives of the mammalian class are of practical importance in biology and veterinary medicine since they are marker signs of their morphofunctional state and criteria for pathomorphological diagnosis of respiratory diseases

Keywords: comparative anatomy; quantitative morphology; respiratory organs; asymmetry coefficient; lung development index

Introduction

A living organism is a complex biological system built from structural elements – organs and tissues that are anatomically interconnected and form a single morphofunctional complex that directly interacts with the environment (Lyabakh, 2019). The response of the animal body to the influence of external factors occurs only during the normal morphofunctional activity of all its systems, including the respiratory apparatus, which includes the lungs (Bilash *et al.*, 2019).

An important and new area of research in morphology is the investigation of adaptive morphofunctional changes in the body of living things to the conditions of external and internal environments (Koptev, 2011; Dzubanovsky

et al., 2019). In addition, identifying the morphological features and functional state of organs and systems in normal conditions will allow effectively correcting vital processes of the body for pathology associated with the respiratory system. Therefore, the study of macro-morphology and organometric parameters of respiratory organs, including lungs in domestic mammals, is important and is a morphological criterion for indicators of the functional state of all important systems of the animal body.

A comprehensive study of the respiratory system, including the lungs, which perform an extremely vital function in humans and animals – gas exchange, is important (Hyde *et al.*, 2009; Johnson-Delaney & Orosz, 2011).

The mammalian respiratory system should be considered as an open system of the body, providing it with several multifunctional adaptive responses to the air environment. This system is one of the most important, providing gas exchange in the mammalian body by saturating the blood with oxygen and removing carbon dioxide from it to the environment (Patwa & Shah, 2015; Samborska, 2021).

The lungs are soft, compact, parenchymal tissue. They are located in the pleural cavity within the chest (Ramchandani *et al.*, 2019). The lungs in mammals are usually formed by the lobes of the lungs, which is due to the need to stretch them in different areas (Ramchandani *et al.*, 2003). The typical division of the lungs into lobes is not observed in all placental animals. In primitive placental animals (most insectivores, many rodents, etc.), this division is not detected: the left lung is usually not divided into lobes and the right lung is represented by incomplete lobular division (according to the number of lobes) or indistinctly expressed lobe clippings (Ferner *et al.*, 2017). The lungs of different animal species have individual morphofunctional features regarding their lobular structure (Ramchandani *et al.*, 2019). Some foreign morphologists believe that in mammals, the lobular structure of the lungs is natural and has no specific features (Duncan, 2004).

The degree of morphofunctional complexity of lung organisation varies in animals: it is simpler in lower terrestrial vertebrates and becomes more complex as their overall organisation increases (Patra, 1986).

The lungs, according to many researchers, belong to the immunocompetent organs (Moyron-Quiroz *et al.*, 2004). Thus, in the protection of the lungs from damage, and in the pathogenesis of many respiratory diseases, the main importance is the pulmonary part of the mononuclear phagocyte system (Hiemstra,

2016). The state of the cellular component, mobilisation ability, and functional reserves determine the resistance of lung tissue to infections, exogenous and endogenous toxins (Wright, 2004).

An urgent task of modern morphology is to examine the morphofunctional features of animal body systems and establish their adaptive capabilities, including the respiratory organs, which include the lungs. Lungs in mammals are paired parenchymal organs that perform the function of gas exchange and others: metabolic, secretory, barrier, excretory, thermoregulatory and, thereby, take part in ensuring the homeostasis of the body. The internal structural basis of the lungs consists of numerous lobes that have a cone-shaped or pyramidal shape. Moreover, indicators of morphohistological architectonics of respiratory organs are not only of cognitive importance for fundamental disciplines but also serve as a clinical basis for veterinary medicine.

Therefore, the purpose of this study was to establish the macroscopic comparative structure of the lungs and conduct an organometric assessment of their morphological structures in domestic sexually mature animals belonging to the Mammals class – *Mammalia*.

The following tasks were set to achieve the stated purpose:

- ◆ conduct organometric studies of the lungs to determine their linear (length, width, thickness) and weight (absolute and relative mass) indicators in domestic mammals;
- ◆ perform morphometric analysis of structural components to determine their linear and weight parameters of the pulmonary lobes (cranial, cardiac, caudal, additional) of the right and left lungs in domestic mammals;
- ◆ develop a morphological scale of regularities in the formation of the lung development index to determine the normal shape of the lungs.

Literature review

The parenchymal organ is a complex morphological structure that performs certain functions of interaction with other anatomically and functionally related organs, takes part in the exchange of energy and plastic substances in the animal's body during individual development. Specific features of the organ structure are not only a consequence of a high degree of adaptation of the animal body but can also be a consequence of the development of various pathological processes.

There is no doubt that studies of the morphophysiological state of the animal body always remain the most important in the morphological area in both biological and veterinary and medical studies (Kryshforova *et al.*, 2015; Archer *et al.*, 2021). In this regard, they are widely used to establish the indicators of the physiological norm in the diagnosis of diseases of various origins, in assessing the impact of conditions of keeping and feeding animals, ways to increase their productivity, etc.

A number of researchers focus on morphological research methods (Weibel, 2017; Archer *et al.*, 2021). Thus, morphological indicators – the volume of the organ in general and its individual structural units, and absolute and relative mass are considered optimal parameters for macroscopic assessment, which allows reconstructing the quantitative and spatial relationships of structural elements of the animal body. Therefore, there is no doubt that an important criterion for the development of an organ is its absolute mass, which directly indicates its morphofunctional maturity. Therewith, the relative mass of the lungs directly depends on the body weight of the animal and the absolute mass of the organ.

The process of respiration is a source of energy necessary to ensure the vital activity of the body. Researchers around the world are actively engaged in respiratory research. Thus,

the human and animal respiratory systems, as the entire organic nature in general, show a morphofunctional pattern of continuous unity and interdependence of anatomical structure and function (Blagojević *et al.*, 2018). This is no coincidence because researchers note a clear link between the morphological structures of the respiratory system and other body systems (Johnson-Delaney & Orosz, 2011).

The lungs are constantly exposed to various environmental influences. Thus, mechanical particles, microorganisms, and gases can enter the lungs from the air, which negatively affects pulmonary homeostasis and thereby increase the vulnerability of the organ to infectious agents. The authors (Khoury *et al.*, 2022) established that a substantial area of the alveolar surface of the lungs and constant contact with dangerous environmental factors create potential conditions for the development of infections. Han *et al.* (2015) note the ability of the respiratory system to remain relatively resistant to various pathogens, which is explained by an effective body defence system (Han & Mallampalli 2015). However, despite preventive measures in animal husbandry, recently, many researchers have noted a tendency to increase respiratory diseases, including lung pathology (Hiemstra, 2016; Williams & Roman, 2016). Surgical treatment, correct interpretation of research results and prevention of these diseases are impossible without knowledge of the features of comparative morphology and topography of organs in accordance with physiological characteristics.

Therefore, the study of structural and functional features of the macro- and microscopic structure of the lungs in domestic animals remains an urgent issue today of the mammalian class (*Mammalia*): *Oryctolagus cuniculus* L., 1758 – European rabbit; *Sapius familiaris* L., 1759 – domestic dog; *Sus scrofa, forma domestica* L., 1758 – domestic pig; *Ovis aries* L.,

1758 – domestic ram (sheep); *Bos Taurus L.*, 1758 – domestic bull; *Equus ferus Caballus L.*, 1758 – domestic horse. Therewith, it is necessary to consider organometric studies to form morphological criteria (marker features) of the organ. The results of such studies, considering the use of morphological marker criteria developed by the authors for assessing the morphofunctional state of the lungs in clinically healthy animals, will not only have cognitive importance but will also be the basis as indicators of the norm for the prevention and diagnosis of diseases of various origins. They will also be important for the comparative anatomy of investigating the constitution of animals in zootechnics and contribute to the successful development of the livestock industry, improving the productive qualities of animals, etc.

Materials and Methods

The studies were conducted by employees of the Department of Normal and Pathological Morphology, Hygiene, and Expertise of Polissia National University during 2021-2023.

Experimental animals were selected according to the principle of analogues, breed and age. The paper uses 30 individuals of 6 species of animals belonging to the class *Mammalia* – Mammals: *Oryctolagus cuniculus L.*, 1758 – European rabbit; *Sapis familiaris L.*, 1759 – domestic dog; *Sus scrofa, forma domestica L.*, 1758 – domestic pig; *Ovis aries L.*, 1758 – domestic ram (sheep); *Bos Taurus L.*, 1758 – domestic bull; *Equus ferus Caballus L.*, 1758 – domestic horse.

The fresh lungs of the examined animals were subjected to anatomical preparation. During the study, the general rules of good laboratory practice GLP (1981) and the provisions of the “Ethical Guidelines for the Use of Animals in Research”, adopted by the First National Congress on Bioethics (Kyiv, 2001), were observed. The entire experimental part of the

study was conducted in accordance with the requirements of the international principles of the “European Convention for the Protection of Vertebrate Animals used for Experimental and other Scientific Purposes” (Strasbourg, 1986) (European Convention, 1986), “Rules for Conducting Work Using Experimental Animals”, approved by the order of the Ministry of Health No. 281 of November 1, 2000 “On measures for further improvement of organisational forms of work using experimental animals” and the relevant Law of Ukraine “On the protection of animals from ill-treatment” (No. 3447-IV of 21.02.2006, Kyiv) (Law of Ukraine, 2006; Mishalov et al., 2007).

Lungs from clinically healthy animals were selected for macroscopic studies and organometric analysis (n = 5). After the autopsy, the shape of the lungs and their location in the chest cavity were determined, the absolute and relative mass, length, width, and thickness of the organ lobes were identified.

The absolute mass of the lungs and their lobes was determined by weighing on a laboratory scale RADWAG PS 6000/C/2 (Poland). The relative mass of the lungs (RM) was calculated by the formula (1):

$$RM = \frac{AM}{MA} * 100\%, \quad (1)$$

where *AM* – the absolute mass of the lungs; *MA* – mass of the animal.

Determination of linear parameters of the organ (length, width, and thickness) was conducted by direct measurement with a marking ruler LR 1000 (Ukraine).

The coefficient of asymmetry (CA) of the lungs was determined by the formula (2):

$$CA = \frac{AMRL}{AMLL}, \quad (2)$$

where: *AMRL* – the absolute mass of the right lung; *AMLL* – the absolute mass of the left lung.

The lung development index (LDI) was determined by the ratio of their total length to width using the formula (3):

$$LDI = \frac{LO}{WO} * 100\%, \quad (3)$$

where: *LO* – the length of the organ; *WO* – width of the organ.

According to the indicator of the lung development index, the shape (types) of the lungs were determined (expanded-shortened, intermediate, moderately elongated, elongated): in the case of the LDI value: 85-100%, it is defined as expanded-shortened; according to the LDI indicator: 101-120% – as intermediate, according to the LDI indicator: 121-130% – moderately elongated, according to the LDI indicator: 131-140% – elongated.

Based on the outlined tasks of morphological studies, the following stages were performed: preparation of lungs; description of their shape and structure; organometry, which included determining linear measurements of the lungs (length, width, thickness); clarification of the absolute and relative mass of the lungs and their lobes (left and right);

determination of absolute and relative indicators of the lungs.

The names of morphological structures of the lungs are presented in accordance with the requirements of the International Veterinary Anatomical Nomenclature (Khomych, 2005).

Digital data was processed using variational and statistical methods on a personal computer using the Microsoft Excel programme. Therewith, the arithmetic mean (*M*) and statistical error of the arithmetic mean (*m*), the probability of the difference between the arithmetic mean of two variational series were determined – according to the probability criterion (*P*) and the student's tables. The difference between the two values was considered substantial at $P < 0.05$; $P < 0.01$; $P < 0.001$.

Results and Discussion

The lungs of domestic mammals, according to the symmetry of their body, are divided into left and right and have a lobular structure (Autifi, *et al.*, 2009). An important criterion for the development of an organ, which directly indicates its morphofunctional maturity, is the absolute mass (Fig. 1) (Prokushenkova, 2009).

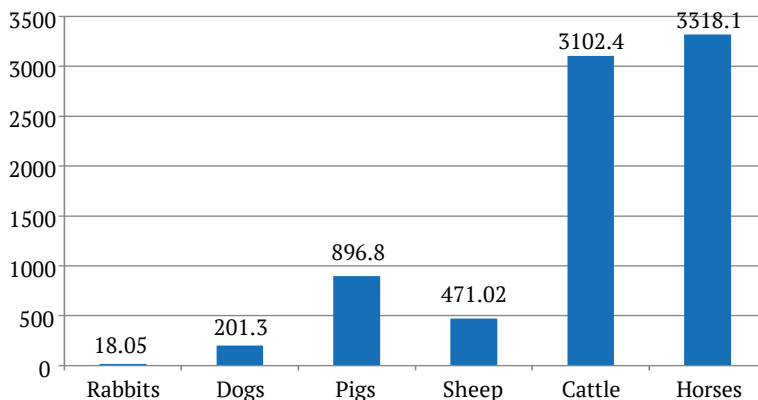


Figure 1. Specific features of the absolute lung mass of domestic mammals (g)

The relative mass of lungs in domestic mammals varies (Maina, 1988). According to

the results obtained, the highest relative lung mass in dogs is $1.21 \pm 0.14\%$ (Fig. 2).

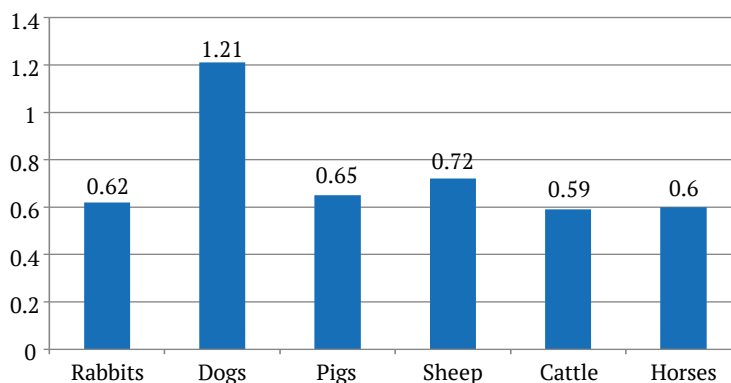


Figure 2. Specific features of the relative lung mass of domestic mammals (%)

The established feature is assumably due to the fact that this animal species has frequent and vigorous breathing, and the remaining air is used quite quickly. On average, in 1 min, depending on the age and size of the animals and at rest, the dog performs from 14 to 30 breathing movements, and during movement and under other circumstances, the intensity of breathing can increase by 2-2.5 times (Horalskyi *et al.*, 2009). In the remaining animal species examined, the relative lung mass was: in cattle – $0.59 \pm 0.024\%$, in horses – $0.60 \pm 0.052\%$, in rabbits – $0.62 \pm 0.013\%$, in pigs – $0.65 \pm 0.018\%$, in sheep – $0.72 \pm 0.038\%$ (Fig. 2).

According to the classical literature on animal anatomy (Akaevsky *et al.*, 2005), the relative lung mass in horses is equal to 1.43% of the animal's body weight, which does not coincide with the results obtained ($0.60 \pm 0.052\%$) in the context of the conducted research and may be related to the breed characteristics of the examined animal species.

Thus, the absolute and relative mass of lungs in domestic animals, and their morphological structures are different and depend on the specific characteristics of animals, their body weight, and the absolute mass of the organ.

In modern morphology, using morphometric (quantitative) research methods, it is

possible to establish relationships and interdependence between quantitative changes in individual structures of the animal body and their relative characteristics (individual lobes and sites, etc.) at different stages of individual and phylogenetic development. In addition to that, it is essential to consider the functional state of a particular system of the animal body, depending on their species' characteristics (Krishtoforova & Lemeshchenko, 2007; Jensen *et al.*, 2019).

It was established that the right lung in domestic mammals is larger than the left, which is manifested by signs of asymmetry, depending on the animal species (Musabayeva *et al.*, 2017; Blagojević *et al.*, 2018; Goralsky *et al.*, 2020).

Some researchers (Kling, 2011) consider the manifestation of lung asymmetry in domestic mammals to be a genetic trait. Others claim (Pantoja, *et al.*, 2020) that the asymmetry is associated with the asymmetric position of the heart and other organs in the chest cavity, which depends on the intensity of their gas exchange function, which was manifested during the evolutionary development of animals (Samborska, 2021). According to the literature data, the ratio of the size of the left to right lung is 1.21:1 in horses, 1.38:1 in cattle, 1.35:1 in pigs, and 1.32:1 in dogs (Rudik *et al.*, 2001).

According to the results of organometric studies of the authors in domestic mammals, the right lung is slightly larger than the left, since the heart is shifted to the left. Therefore, the pronounced asymmetry of the lungs occurs due to the different absolute mass of the right lung to the left, the development index of which is equal to: in rabbits – 1:1.30, in dogs – 1:1.33, in sheep – 1:1.37, in pigs – 1:1.34, in cattle – 1:1.37, in horses – 1:1.2.

In most domestic mammals, the left lung has three lobes (cranial, middle, and caudal), and the right lung has four lobes (cranial, middle, caudal, and complementary) (Kling, 2011; Prohl *et al.*, 2014).

The peculiarity of the lungs of horses is that their division into lobes is poorly expressed (the middle and caudal lobes have merged into one and form a caudal lobe), and on their sharp edge there is an inclined interlobular gap that divides each lung into cranial

(smaller) and caudal (larger) lobes. The right lung also has an additional lobe. As a result of this evolutionary restructuring of the lungs, their shape and size in general, and lobes in particular, and, as a rule, the absolute and relative mass of individual lobes to the total absolute mass of the lungs, have changed. This is not accidental, since the diversity of lung shapes according to their lobular structure, which is observed in mammals, obeys certain laws of their adaptive changes in the course of evolution (Prokushenkova, 2009). Therefore, depending on the type of animal, in the process of evolutionary development, the shape of the lungs in general and the lobes in particular, their absolute and relative mass, changes.

The caudal lobes of the right lung have the highest value of the absolute mass index in experimental animals (Table 1). In the left lung, the examined indicators are slightly lower than in the right.

Table 1. Specific features of the absolute mass of lung lobes of domestic mammals (g), $M \pm m$, $n = 5$

Lung lobes	Animal species						
	rabbits	dogs	pigs	sheep	cattle	horses	
Cranial	left	0.79±0.03	22.09±3.01	62.59±8.02	39.58±4.08	259.98±29.02	197.43±19.24
	right	1.71±0.06***	27.29±3.21	82.17±8.96	56.12±6.04	318.31±38.16	214.02±24.04
Middle	left	1.49±0.05	19.91±2.84	72.73±9.21	30.36±2.31	292.25±31.38	–
	right	1.98±0.07***	23.65±2.96***	102.72±11.04	35.06±3.26	402.69±40.02	–
Caudal	left	5.56±0.32	44,26±6,02	247.88±28.04	129.10±10.02	756.98±67.93	1308.66±98.75
	right	5.63±0.41	47.96±6.38	26.07±29.48	164.08±16.17	903.78±72.18	1423.8±102.71
Additional	left	–	–	–	–	–	–
	right	0.89±0.04	16.14±2.08	61.63±7.48	17.72±1.72	168.41±27.33	174.2±16.02
In all	left	7.84±0.73	86,26±8,01	383,2±28,75	199.04±19.82	1309,21±43,38	1506.1±60.48
	right	10.21±0.91	115.04±10.14*	513.6±49.88*	272.98±26.91*	1793.19±54.87***	1812.0±62.92**
Absolute mass of both lungs		18.05±1.02	201.3±18.4	896.8±50.66	472.02±46.34	3102.4±98.62	3318.1±364.4
Coefficient of asymmetry (CA) of the lungs		1:1.30	1:1.33	1:1.34	1:1.37	1:1.37	1:1.2

Note: * $P < 0.05$; ** $P < 0.01$; *** $P < 0.001$ the right lobe of the lungs compared to the left

Therewith, in all experimental animal species, there is only a tendency to increase the absolute mass of the right lung to the left (Table 1). High values of the results of the absolute mass of the caudal lobes of the lungs in domestic mammals are associated with morphotopography of the lungs, their functional load in general, and the pulmonary lobes in particular, during pulmonary (external) respiration (Horalsky, *et al.*, 2009).

Lower morphometric values are characteristic of the cranial lobes of the lungs (Table 1). The absolute mass of the left lobe of the lungs in rabbits and sheep is substantially less by 2.2 times ($P < 0.001$) and 1.4 times ($P < 0.05$) compared to the right one. Therewith, in dogs, pigs, cattle, and horses, there is a tendency to increase the ratio of the mass of the right lung to the left (Table 1).

Therewith, the absolute mass of the middle lobes of the right and left lungs in most experimental mammals has an intermediate value compared to the same indicator of the cranial and caudal lobes (except for dogs and sheep, in

which the absolute mass of such lobes is greater than that of the cranial lobes). The absolute mass of the middle lobe of the left lung almost does not change in relation to the right in all the examined animals, so there is only a tendency to reduce this indicator: in rabbits – by 1.3 times, in dogs – by 1.2 times, in pigs – by 1.4 times, in sheep – by 1.2 times, and cattle – by 1.4 times. In the lungs of horses, this middle part is absent.

Among the examined indicators (Table 1), the lowest absolute mass index is set for the additional proportion of lungs in all the examined animals.

According to the results obtained, the ratio of the relative mass of anatomical parts of the lungs (Fig. 3) (cranial, medium, caudal, additional lobes) to the average absolute mass of the lungs is directly proportional to the body mass of animals and the absolute mass of the organ and varies depending on the indicators of the absolute mass of the lobes and the absolute mass of the lungs, which also coincides with the results of other researchers (Maina & Igbokwe, 2020; Pantoja *et al.*, 2020).

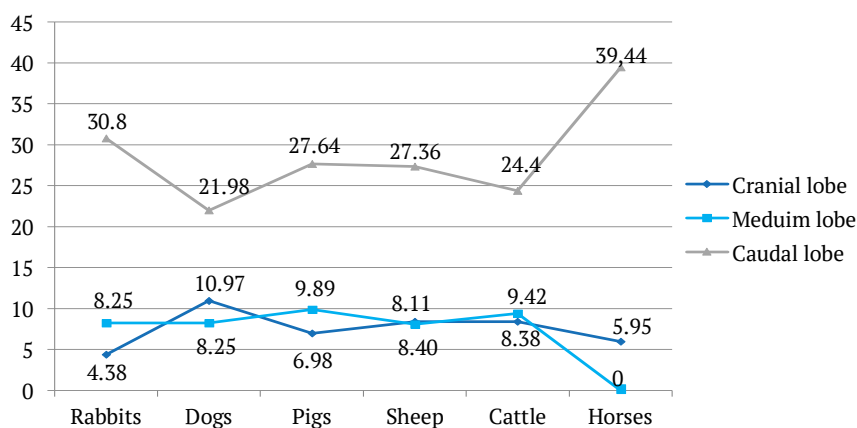


Figure 3. Specific features of the relative mass of the left lung lobes of domestic mammals (%)

According to the results of morphometric studies, the caudal lobes of the right and

left lungs have the largest total mass, which depends on the absolute mass of the lobes.

In the right lung of rabbits, this indicator is $31.19 \pm 1.38\%$, in dogs – $23.83 \pm 1.82\%$, in pigs – $29.79 \pm 1.37\%$, in sheep – $34.76 \pm 3.04\%$, in cattle – $29.13 \pm 2.54\%$, in horses – $42.91 \pm 4.06\%$. In the left lung, the relative mass of caudal lobes in accordance with the total absolute mass of the lungs is: in rabbits – $30.8 \pm 1.54\%$; in dogs – $21.98 \pm 1.82\%$; in pigs – $27.64 \pm 1.66\%$; in sheep – $27.35 \pm 2.36\%$; in cattle – $24.4 \pm 1.92\%$, and in horses – $39.44 \pm 3.57\%$ (Fig. 3). Therewith, the largest percentage of the relative mass of the caudal lobes of the lungs of horses (Fig. 3) can be explained by the absence of middle pulmonary lobes in the lungs.

Compared to other indicators examined, the cranial lobes of the lungs of animals have a lower relative mass. However, in the right lung, the relative mass of cranial lobes (in rabbits – $9.47 \pm 0.89\%$, dogs – $13.56 \pm 0.92\%$, sheep – $11.89 \pm 1.07\%$, pigs – $11.89 \pm 1.07\%$, cattle – $10.26 \pm 0.97\%$, horses – $6.45 \pm 0.62\%$) is higher relative to such indicators in the left lung (in rabbits – $4.38 \pm 0.31\%$, dogs – $10.97 \pm 0.96\%$, pigs – $6.98 \pm 0.67\%$, sheep – $8.4 \pm 1.04\%$, cattle –

$8.38 \pm 0.64\%$, and horses – $5.95 \pm 0.51\%$ (Fig. 3), which is consistent with the results of other researchers (Maina & Igbokwe, 2020; Pantoja *et al.*, 2020).

The relative mass of the middle lobes of the lungs in experimental animals varies but is lower compared to that of the caudal lobes. However, their organometric data are slightly larger than the relative mass of cranial lobes. However, in dogs, the relative mass of the middle lobes is greater than that of the cranial lobes (Fig. 4). The relative mass of the middle lobes of the right lung in rabbits is $10.97 \pm 0.98\%$, in dogs – $11.75 \pm 1.14\%$, in pigs – $11.45 \pm 1.04\%$, in sheep – $7.42 \pm 0.88\%$, and in cattle – $12.98 \pm 1.32\%$. Therewith, the relative mass of the lobes of the left lung is lower compared to the right lung and is: in rabbits – $8.25 \pm 0.81\%$, in dogs – $9.89 \pm 0.64\%$, in pigs – $8.11 \pm 0.72\%$, in sheep – $6.43 \pm 0.62\%$ and in cattle – $9.42 \pm 0.88\%$ (Fig. 4). Additional lung lobes have the lowest relative weight: rabbits – $4.93 \pm 0.36\%$, dogs – $8.02 \pm 0.48\%$, pigs – $6.87 \pm 0.64\%$, sheep – $3.75 \pm 0.12\%$, cattle – $5.42 \pm 0.56\%$, and horses – $5.25 \pm 0.68\%$ (Fig. 4).

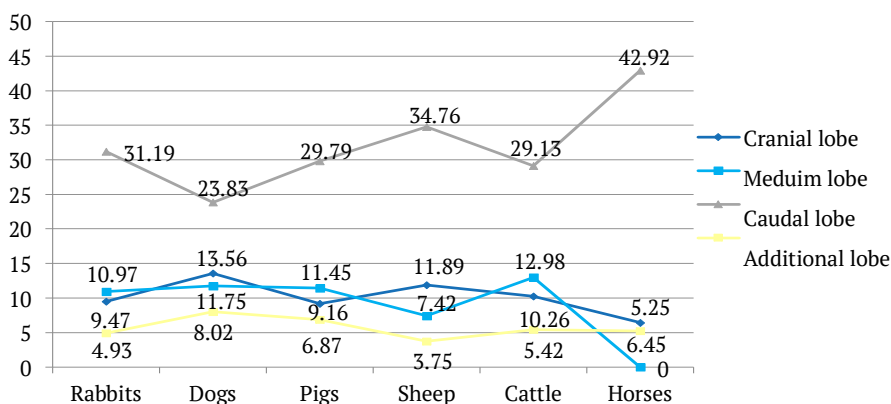


Figure 3. Specific features of the relative mass of right lung lobes of domestic mammals (%)

Thus, analysing the results of lung morphometry in domestic mammals, it was established that the absolute and relative mass of

lung lobes (cranial, medium, caudal, additional) depend on the morphotopography of the lungs, functional load, and species characteristics of

experimental animals. Therewith, the lowest absolute mass of all lung lobes was established in rabbits (the smallest animals), slightly higher in dogs, then sheep, pigs, and the highest in cattle and horses, which are the largest an-

imals in terms of body weight. Analysing the organometric linear parameters of the lungs of domestic mammals, it should be noted that the greatest total length, width and thickness of the lungs were determined in horses (Table 2).

Table 2. Specific features of linear lung measurements of domestic mammals (cm), $M \pm m$, $n = 5$

Indicator	Animal species						
	rabbits	dogs	pigs	sheep	cattle	horses	
Total length	7.2±0.50	23.0±2.42	35.3±2.82	25.6±2.98	55.15±4.58	61.5±6.32	
Total width	7.98±0.54	16.7±1.34	25.8±1.79	22.4±2.90	47.08±3.59	48.44±4.14	
Total thickness	1.52±0.20	1.9±0.36	3.6±1.30	5.1±1.12	7.68±1.02	9.6±1.1	
Lung development index, (%)	90±1.89	137±2.84	136±3.01	114±2.08	117±2.21	127±2.74	
Left lung	length	6.4±0.45	20.2±0.24	29.8±1.90	21.1±1.90	47.34±3.46	60.35±6.96
	width	3.54±0.32	7.6±0.54	10.5±0.30	10.7±1.67	21.5±1.10	23.51±1.44
	thickness	1.28±0.38	1.5±0.09	3.3±1.21	5.0±1.01	7.49±1.32	9.1±1.37
Right lung	length	7.01±0.40	22.9±2.18	35.2±2.41	25.4±2.4	55.04±4.41	61.84±6.39
	width	4.18±0.36	8.1±0.62	12.2±1.34	12.1±1.76	23.2±1.04	23.9±1.42
	thickness	1.52±0.34	1.8±0.11	3.6±1.30	5.1±1.10	7.60±1.34	9.64±1.48

According to Table 2, the smallest indicators of the total length, width and thickness of the lungs, in particular, the right and left lungs, were determined in rabbits. Linear lung parameters increase in accordance with the increase in body weight of animals. Therewith, the linear characteristics (length, width, thickness) of the right lung in all types of experimental animals are larger than the left, and accordingly, the development index (ratio of length to width) of the lungs in domestic animals has different values (Table 2).

Analysing the results obtained in detail, considering the macroscopic structure of the lungs, their asymmetry coefficient (the ratio of the absolute mass of the right lung to the left), a morphological scale was developed to determine the lung development index (marker signs). According to the morphological scale, the lungs of domestic mammals were classified according

to their structure and shape into 4 types: 1st – expanded-shortened (LDI = 85–100%); 2nd – intermediate (LDI = 101–120%); 3rd – moderately elongated (LDI = 121–130%); 4th – elongated (LDI = 131–140%). According to the proposed scale for assessing marker signs of lungs in clinically healthy animals, their development index differs: in rabbits, the LDI is $90 \pm 1.89\%$, so their lungs are expanded-shortened type; in cattle and sheep, this indicator is $117 \pm 2.21\%$ and $114 \pm 2.08\%$, respectively, and their lungs are characterised as expanded-elongated type; in horses, the LDI is $127 \pm 2.74\%$, so their lungs are moderately elongated type; in pigs and dogs, LDI, respectively, is $136 \pm 3.01\%$ and $137 \pm 2.84\%$, and therefore their lungs are elongated.

Conclusions

According to the symmetry of the animal body, the lungs are divided into left and right and have

a typical partial structure: the left lung in all experimental animals (except horses) has three lobes – cranial, middle, caudal; and the right four – cranial, middle, caudal, and additional. In horses, the interlobular cardiac notch divides the right and left lungs into only two lobes – the cranial (much smaller) and caudal (larger), and the right lung has an additional lobe on the medial side. The left lung is much smaller than the right.

According to the results of the study, the absolute mass of lungs in representatives of domestic mammals (the smallest in rabbits – 18.05 ± 1.32 g, the largest in horses – 3318.1 ± 364.4 g) synchronously obeys the well-known and recognised facts of organ development and depends on the phylogenetic level of animal development. The higher the systematic ratio of animal species (their size, body weight, etc.), the greater the organometric parameters of the organ.

The relative lung mass in experimental mammals varies asynchronously, depending on the animals' body weight and absolute lung mass. Thus, the highest relative weight in dogs is $1.21 \pm 0.14\%$ and the lowest in cattle – $0.59 \pm 0.024\%$. The intermediate value of the relative lung mass index is typical for horses ($0.60 \pm 0.052\%$), rabbits ($0.62 \pm 0.013\%$), pigs ($0.65 \pm 0.018\%$), and sheep ($0.72 \pm 0.038\%$).

In domestic mammals, considering the specific characteristics of animals, depend-

ing on the type of respiration characteristic of them, the lungs are different in shape and size, and therefore differ in the parameters of the development index: in rabbits ($LDI = 90 \pm 1.89\%$), the lungs are expanded-shortened type; in cattle ($LDI = 117 \pm 2.21\%$), and sheep ($LDI = 114 \pm 2.08\%$) – expanded-elongated type; in horses ($LDI = 127 \pm 2.74\%$) – moderately elongated type; in pigs ($LDI = 136 \pm 3.01\%$), and dogs ($LDI = 137 \pm 2.84$) – elongated type.

In domestic mammals, there is a pronounced asymmetry of the lungs (the ratio of the absolute mass of the left lung to the right), the coefficient of which in rabbits is 1:1.30, dogs – 1:1.33, sheep – 1:1.37, pigs – 1:1.34, cattle – 1:1.37 and horses – 1:1.2.

The scientific originality of these studies consists in the scientific substantiation of the obtained results of morphometric studies, linear parameters, absolute and relative values of lungs, and their lobes in domestic mammals. In the future, it is planned to conduct histo- and ultramicroscopic studies of the respiratory part of the lungs of domestic animals.

Acknowledgements

None.

Conflict of Interest

None.

References

- [1] Akaevsky, A.I., Dichev, Yu.F., & Seleznev, S.B. (2005). *Anatomy of prenatal animals*. Moscow: Aquarium-Print.
- [2] Archer, F., Bobet-Erny, A., & Gomes, M. (2021). State of the art on lung organoids in mammals. *Veterinary Research*, 52(1), article number 77. doi: [10.1186/s13567-021-00946-6](https://doi.org/10.1186/s13567-021-00946-6).
- [3] Autifi, M.A.H., El-Banna, A.K., & Ebaid, A.E.-S. (2015). Morphological study of rabbit lung, bronchial tree and pulmonary vessels using corrosion cast technique. *AL-Azhar Assiut Medical Journal*, 13, 41-50. <http://www.aamj.eg.net/journals/pdf/2352.pdf>.
- [4] Bilash, S.M., Pronina, O.M., & Koptev, M.M. (2019). The value of complex morphological research for modern medical science. Literature review. *Bulletin of Problems of Biology and Medicine*, 2(151), 20-23. doi: [10.29254/2077-4214-2019-2-2-151-20-23](https://doi.org/10.29254/2077-4214-2019-2-2-151-20-23).

- [5] Blagojević, M., Božičković, I., Ušćebrka, G., Lozanče, O., Đorđević, M., Zorić, Z., & Nešić, I. (2018). Anatomical and histological characteristics of the lungs in the ground squirrel (*Spermophilus citellus*). *Acta Veterinaria Hungarica*, 66(2), 165-176. doi: 10.1556/004.2018.016.
- [6] Duncker, H.R. (2004). Vertebrate lungs: structure, topography and mechanics: A comparative perspective of the progressive integration of respiratory system, locomotor apparatus and ontogenetic development. *Respiratory Physiology & Neurobiology*, 144, 111-124.
- [7] Dzubanovsky, I.Ya., Vervega, B.M., Pidručna, S.R., & Melnyk, N.A. (2019). Morphologic characteristic of the lungs in the patients, suffering experimental peritonitis. *Klinichna khirurgiia*, 86(8), 72-75. doi: 10.26779/2522-1396.2019.08.72.
- [8] European Convention for the protection of vertebrate animals used for research and other scientific purposes. (1986, March). Retrieved from https://zakon.rada.gov.ua/laws/show/994_137#Text.
- [9] Ferner, K., Schultz, J. A., & Zeller, U. (2017). Comparative anatomy of neonates of the three major mammalian groups (monotremes, marsupials, placentals) and implications for the ancestral mammalian neonate morphotype. *Journal of Anatomy*, 231(6), 798-822. doi: 10.1111/joa.12689.
- [10] Goralsky, L.P., Glukhova, N.M., & Sokulsky, I.M. (2020). Morphological features of rabbit lungs. *Scientific Horizons*, 93(8), 180-188. doi: 10.33249/2663-2144-2020-93-8-180-188.
- [11] Han, S., & Mallampalli, R.K. (2015). The acute respiratory distress syndrome: from mechanism to translation. *Journal of immunology (Baltimore, Md. : 1950)*, 194(3), 855-860. doi: 10.4049/jimmunol.1402513.
- [12] Hiemstra, P.S., Amatngalim, G.D., van der Does, A.M., & Taube, C. (2016). Antimicrobial Peptides and Innate Lung Defenses: Role in Infectious and Noninfectious Lung Diseases and Therapeutic Applications. *Chest*, 149(2), 545-551. doi: 10.1378/chest.15-1353.
- [13] Horalskyi, L.P., Khomych, V.T., & Kononskyi, O.I. (2019). *Fundamentals of histological technique and morphofunctional research methods in normal and pathology*. Zhytomyr: Polissia.
- [14] Horalskyi, L.P., Khomych, V.T., Shikh, Yu.S., Dekhtyaryov, P.A., & Samoiluk, V.V. (2009). *Anatomy and physiology of dogs with the basics of training*. Zhytomyr: Polissia.
- [15] Hyde, D.M., Hamid, Q., & Irvin, C.G. (2009). Anatomy, pathology, and physiology of the tracheobronchial tree: emphasis on the distal airways. *Journal of Allergy and Clinical Immunology*, 124(6), 72-77. doi: 10.1016/j.jaci.2009.08.048.
- [16] Jensen, B., Wang, T., & Moorman, A.F.M. (2019). Evolution and Development of the Atrial Septum. *The Anatomical Record*, 302(1), 32-48. doi: 10.1002/ar.23914.
- [17] Johnson-Delaney, C.A., & Orosz, S.E. (2011). Rabbit respiratory system: clinical anatomy, physiology and disease. *The veterinary clinics of North America. Exotic Animal Practice*, 14(2), 257-266. doi: 10.1016/j.cvex.2011.03.002.
- [18] Khomych, V.T. (2005). *Nomina embryologica veterinaria: In Latin, Ukrainian and English*. Kyiv: Polissia.
- [19] Khoury, O., Clouse, C., McSwain, M.K., Applegate, J., Kock, N.D., Atala, A., & Murphy, S.V. (2022). Ferret acute lung injury model induced by repeated nebulized lipopolysaccharide administration. *Physiological Reports*, 10(20), article number e15400. doi: 10.14814/phy2.15400.

- [20] Kling, M.A. (2011). A review of respiratory system anatomy, physiology, and disease in the mouse, rat, hamster, and gerbil. *The Veterinary Clinics of North America. Exotic Animal Practice*, 14(2), 287-337. doi: [10.1016/j.cvex.2011.03.007](https://doi.org/10.1016/j.cvex.2011.03.007).
- [21] Koptev, M.M. (2011). Morphological and functional characteristics of structural elements in healthy rats' lungs. *Bulletin of the Ukrainian Medical Stomatological Academy*, 4(36), 92-94.
- [22] Krishtoforova, B., & Lemeshchenko, V. (2007). Structural-and-functional peculiarities of hepatic veins and components of tissue in piglets of neonatal period. *Acta Biologica Szegediensis*, 51(1), 24-25.
- [23] Kryshthoforova, B.V. Lemeschenko, V.V., & Stegney, Zh.G. (2015). Prolife morphological criteria of the body status of calves in the neonatal period. *Scientific Messenger of Lviv National University of Veterinary Medicine and Biotechnologies named after S.Z. Gzhytskyj*, 61(1), 82-87.
- [24] Law of Ukraine No. 3447-IV "About protection of animals from cruelty". (2006, February). Retrieved from <https://zakon.rada.gov.ua/laws/show/3447-15#Text>.
- [25] Lyabakh, K.G. (2019). Regulation of cell oxygen regime based on free diffusion. *Physiological Journal*, 65(3), 12-21.
- [26] Maina, J.N. (1988). Morphology and morphometry of the normal lung of the adult vervet monkey (*Cercopithecus aethiops*). *The American Journal of Anatomy*, 183(3), 258-267. doi: [10.1002/aja.1001830308](https://doi.org/10.1002/aja.1001830308).
- [27] Maina, J.N., & Igboke, C.O. (2020). Comparative morphometric analysis of lungs of the semifossorial giant pouched rat (*Cricetomys gambianus*) and the subterranean Nigerian mole rat (*Cryptomys foxi*). *Scientific Reports*, 10(1), article number 5244. doi: [10.1038/s41598-020-61873-8](https://doi.org/10.1038/s41598-020-61873-8).
- [28] Mishalov, V.D., Chaikovskiy, Yu. B., & Tverdokhlib, I.V. (2007). About legal, legislative and ethical norms and requirements in the performance of scientific morphological research. *Morphology*, 1(2), 108-115.
- [29] Moyron-Quiroz, J.E., Rangel-Moreno, J., Kusser, K., Hartson, L., Sprague, F., Goodrich, S., Woodland, D.L., Lund, F.E., & Randall, T.D. (2004). Role of inducible bronchus associated lymphoid tissue (iBALT) in respiratory immunity. *Nature Medicine*, 10(9), 927-934. doi: [10.1038/nm1091](https://doi.org/10.1038/nm1091).
- [30] Musabayeva, L.L., Seitov, M.S., & Parshina, T.Yu. (2017). Comparative aspects of the morphology of the heart and lungs of a hare and a domestic rabbit (milk age period). *Almanac of Young Science*, 4, 32-35.
- [31] Pantoja, B.T.S., Silva, A.R.M., Mondego-Oliveira, R., Silva, T.S., Marques, B.C., Albuquerque, R.P., Sousa, J.C.S., Rici, R.E.G., Miglino, M.A., Sousa, A.L., Francioli, A.L.R., Sousa, E.M., Abreu-Silva, A.L., & Carvalho, R.C. (2020). *Morphological study of larynx, trachea, and lungs of Didelphis marsupialis (LINNAEUS, 1758)*. *Veterinary World*, 13(10), 2142-2149. doi: [10.14202/vetworld.2020.2142-2149](https://doi.org/10.14202/vetworld.2020.2142-2149).
- [32] Patra, A.L. (1986). Comparative anatomy of mammali anrespiratory tracts: the nasopharyngeal region and the tracheobronchial region. *Journal of Toxicology and Environmental Health*, 17(2-3), 163-174. doi: [10.1080/15287398609530813](https://doi.org/10.1080/15287398609530813).
- [33] Patwa, A., & Shah, A. (2015). Anatomy and physiology of respiratory system relevant to anaesthesia. *Indian Journal of Anaesthesia*, 59(9), 533-541. doi: [10.4103/0019-5049.165849](https://doi.org/10.4103/0019-5049.165849).
- [34] Prohl, A., Ostermann, C., Lohr, M., & Reinhold, P. (2014). The bovine lung in biomedical research: visually guided bronchoscopy, intrabronchial inoculation and in vivo sampling techniques. *Journal of visualized experiments : JoVE*, (89), article number 51557. doi: [10.3791/51557](https://doi.org/10.3791/51557).

- [35] Prokushenkova, O.H. (2009). Morphology of the lungs of dog puppies in the neonatal period. *Scientific Bulletin of S. Z. Gzytsky Lviv National University of Veterinary Medicine and Biotechnology*, 11(2), 244-247.
- [36] Ramchandani, R., Bates, J.H., Shen, X., Suki, B., & Tepper, R.S. (2001). Airway branching morphology of mature and immature rabbit lungs. *Journal of Applied Physiology (Bethesda, Md.: 1985)*, 90(4), 1584-1592. doi: [10.1152/jappl.2001.90.4.1584](https://doi.org/10.1152/jappl.2001.90.4.1584).
- [37] Ramchandani, R., Shen, X., Gunst, S.J., & Tepper, R.S. (2003). Comparison of elastic properties and contractile responses of isolated airway segments from mature and immature rabbits. *Journal of Applied Physiology (Bethesda, Md. : 1985)*, 95(1), 265-271. doi: [10.1152/japplphysiol.00362.2002](https://doi.org/10.1152/japplphysiol.00362.2002).
- [38] Samborska, I.A. (2021). Comparative characteristics of histological changes in lung tissue in rats of different ages under conditions of hyperhomocysteinemia. *Reports of Vinnytsia National Medical University*, 25(2), 196-200. doi: [10.31393/reports-vnmedical-2021-25\(2\)-02](https://doi.org/10.31393/reports-vnmedical-2021-25(2)-02).
- [39] Weibel, E.R. (2017). Lung morphometry: the link between structure and function. *Cell and Tissue Research*, 367(3), 413-426. doi: [10.1007/s00441-016-2541-4](https://doi.org/10.1007/s00441-016-2541-4).
- [40] Williams, K., & Roman, J. (2016). Studying human respiratory disease in animals--role of induced and naturally occurring models. *The Journal of Pathology*, 238(2), 220-232. doi: [10.1002/path.4658](https://doi.org/10.1002/path.4658).
- [41] Wright, J.R. (2004). Host defense functions of pulmonary surfactant. *Biology of the Neonate*, 85(4), 326-332. doi: [10.1159/000078172](https://doi.org/10.1159/000078172).

Особливості органометрії легень свійських тварин класу Ссавці (*Mammalia*)

Леонід Петрович Горальський

Доктор ветеринарних наук, професор
Житомирський державний університет імені Івана Франка
10008, вул. В. Бердичівська, 40, м. Житомир, Україна
<https://orcid.org/0000-0002-4251-614X>

Наталія Миколаївна Глухова

Здобувач третього (освітньо-наукового) рівня вищої освіти «Доктор філософії»
Поліський національний університет
10002, б-р Старий, 7, м. Житомир, Україна
<https://orcid.org/0000-0002-4129-7889>

Ігор Миколайович Сокульський

Кандидат ветеринарних наук, доцент
Поліський національний університет
10002, б-р Старий, 7, м. Житомир, Україна
<https://orcid.org/0000-0002-6237-0328>

Наталія Леонідівна Колеснік

Кандидат ветеринарних наук, доцент
Поліський національний університет
10002, б-р Старий, 7, м. Житомир, Україна
<https://orcid.org/0000-0001-7741-8753>

Ірина Петрівна Онищук

Кандидат біологічних наук, доцент
Поліський національний університет
10002, б-р Старий, 7, м. Житомир, Україна
<https://orcid.org/0000-0002-2847-8570>

Анотація. Дослідження організму тварин, його морфоархітектоніки, є пріоритетним напрямом для успішного розвитку тваринництва. Мета роботи – з'ясувати макроскопічну будову легень та надати органометричну оцінку їх морфологічних структур у свійських статевозрілих тварин. У дослідженні використані 30 клінічно здорових особин 6 видів тварин, які належать до класу *Mammalia* – Ссавці. За результатами аналізу морфометрії абсолютних і відносних величин легень у свійських ссавців та їх правої і лівої часток встановлено виражену асиметрію, коефіцієнт якої відповідав: у кролів – 1:1,30, у собак – 1:1,33, у овець – 1:1,37, у свиней – 1:1,34, у великої рогатої худоби – 1:1,37, у коней – 1:1,2. Для морфологічної оцінки типових ознак легень, характерних для конкретного виду тварин, запропоновано морфологічну шкалу з маркерних ознак органа. За результатами досліджень запропоновано класифікувати легені свійських ссавців із урахуванням будови та форми за 4 типами: 1-й – розширено-вкорочений (індекс розвитку легень (ІРЛ) = 85–100%); 2-й – проміжний (ІРЛ = 101–120%); 3-й – помірно видовжений (ІРЛ = 121–130%); 4-й – видовжений (ІРЛ = 131–140%). На

основі детального аналізу органометричних досліджень запропоновано шкалу для оцінки маркерних ознак легень – у кролів (ІРЛ = $90 \pm 1,89\%$) віднесено до розширено-вкороченого типу, у великої рогатої худоби (ІРЛ = $117 \pm 2,21\%$) та овець (ІРЛ = $114 \pm 2,08\%$) – проміжного типу, в коней (ІРЛ = $127 \pm 2,74\%$) – помірно-видовженого типу, у свиней (ІРЛ = $136 \pm 3,01\%$) та собак (ІРЛ = $137 \pm 2,84\%$) – видовженого типу. Отримані результати морфологічних досліджень легень представників класу Ссавці мають практичне значення у біології та ветеринарній медицині, оскільки є маркерними ознаками їх морфофункціонального стану та критеріями патоморфологічної діагностики респіраторних захворювань

Ключові слова: порівняльна анатомія; кількісна морфологія; органи дихання; коефіцієнт асиметрії; індекс розвитку легень
