



UDC: 636.2.09: 618.333: 616.99(477)
DOI: 10.31548/ujvs.13(3).2022.50-56

Pathohistological Changes in Aborted Foetuses of Cows Due to Neosporosis: Evidence from Ukraine

Bohdan Nyzhnyk^{1*}, Inna Hrushkovska², Tetiana Kataieva², Oleksandr Valchuk¹

¹National University of Life and Environmental Sciences of Ukraine
03041, 15 Heroiv Oborony Str., Kyiv, Ukraine

²Center of Veterinary Diagnostic LTD
03022, 15a Kaisarov Str., Kyiv, Ukraine

Abstract. Neosporosis is a parasitic disease characterized by abortions and the birth of weak offspring in cows. The causative agent of *Neospora caninum* is an obligate, protozoan parasite that belongs to the type *Apicomplexa*. The relevance of the study is conditioned upon the adverse impact of neosporosis on the economy of Ukraine (loss of productivity, veterinary and diagnostic costs). Furthermore, the issue of neosporosis is understudied. In this regard, the purpose of this study was to establish pathohistological changes in aborted foetuses and the foetal part of placentas and to confirm the involvement of the parasite (*Neospora caninum*) in cases of abortions recorded in different regions of the country. Two methods were used to investigate this problem: histological and real-time polymerase chain reaction. In aborted foetuses positive for *N. caninum*, the following pathohistological changes were most often detected: focal gliosis and perivascular mononuclear infiltrates in the brain; focal or diffuse mononuclear infiltration in the heart and skeletal muscles; periportal mononuclear infiltrates in the liver; focal necrosis of the mucous membrane and mononuclear infiltration in the foetal part of the placenta. Changes were less often detected in the lungs – mononuclear infiltration of the interstitium and diffuse lymphocytic alveolitis, and in the kidneys – diffuse interstitial mononuclear infiltration. No changes were found in the spleen. Neospore-like cysts were found in one out of twelve foetuses. Lesions established of foetal organs and placentas are inherent in neosporosis. The results of histological studies substantially complement the data of other authors, confirm the involvement of *N. caninum* in the occurrence of abortions in cows in certain regions of Ukraine, and also represent practical value for the diagnosis and control of neosporosis in cattle

Keywords: cattle, *Neospora caninum*, abortion, histology

Introduction

Neospora caninum is a unicellular parasite that causes neosporosis, a parasitic disease that results in reproductive problems, namely abortions in cows [1-3]. Furthermore, the disease is widespread in the world, as evidenced by a meta-analysis conducted by Tooran Nayeri *et al.*, [4] and about 3,000 scientific papers on this topic [5].

The parasite was first detected in the brain and skeletal muscle of Boxer puppies in Norway in 1984 [6] and

described in 1988 [7]. The causative agent *N. caninum* was first isolated from aborted foetuses of cows in 1993 [8].

Dogs, coyotes, wolves, and dingoes have been identified as definitive hosts of *N. caninum*, while cattle, deer, sheep, buffalo, bison, rodents, birds, and horses are intermediate hosts [9]. In cows, infection with the parasite can occur from mother to foetus, and in the postnatal period – due to ingestion of sporulated oocysts [10; 11].

Suggested Citation:

Nyzhnyk, B., Hrushkovska, I., Kataieva, T., & Valchuk, O. (2022). Pathohistological changes in aborted foetuses of cows due to neosporosis: Evidence from Ukraine. *Ukrainian Journal of Veterinary Sciences*, 13(3), 50-56.

*Corresponding author

Pathohistological changes that most often occur in foetuses and placentas infected with *N. caninum* include periportal hepatitis and multifocal hepatocellular necrosis; myocarditis and pericarditis; perivascular infiltrates, focal necrosis and foci of gliosis in the brain; non-purulent myositis; focal necrosis and non-purulent placentitis [12-14]. These changes do not have a clear localization and correspond to different severity of the lesion [15-17].

Ahmad Nematollahi *et al.* described similar pathohistological changes in infected foetuses: acute congestion, perivascular and perineuronal oedema, spongiosis, perivascular infiltrates, focal gliosis and necrosis were noted in the brain and spinal cord; in the placenta – vasculitis, acute congestion, perivascular infiltration with mononuclear cells, vascular thrombosis, focal placentitis and necrosis in the cotyledons; in the heart – focal pericarditis and focal haemorrhages [18].

Amir Kamali *et al.* investigated 56 brain samples of aborted foetuses, of which 16 (28%) showed non-purulent encephalitis inherent in neosporosis. Acute hyperaemia (100%), oedema (100%), gliosis (93%), perivascular infiltrates (63%), haemorrhages (51%), focal necrosis (25%), non-purulent meningitis (5%), and satellitosis (2%) were also noted in this study [19].

In the brain, heart, liver, lungs, kidneys of 34 foetuses infected with *N. caninum*, histological studies by Esther Collantes-Fernández *et al.* established multiple centres of non-purulent infiltrates with multifocal necrotic areas surrounded by inflammatory cells. According to their data, the affected organs were the heart, liver, and brain, less affected – the lungs and kidneys [20].

As a result of statistical analysis of the published data, it was found that in 85% of cases, pathological changes in aborted foetuses are mainly localized in the central nervous system [21]. Furthermore, researchers from Brazil and Greece emphasize the influence of the parasite on the reproductive system, which adversely affects the reproduction rates of cattle [22; 23].

Neosporosis causes significant economic losses both at the level of individual livestock farms and in the entire livestock industry due to the deterioration of reproduction indicators, reduced productivity and the costs associated with preventive measures [24-26]. This disease is difficult to control since there is no specific treatment and affordable and efficacious vaccine prevention.

In Ukraine, there are laboratory-confirmed cases of abortions caused by *N. caninum* [27] and, since there are only isolated reports on this issue, the purpose of this study is to evaluate pathohistological changes in aborted foetuses and the foetal part of placentas and to confirm the involvement of *N. caninum* in recorded cases of cow abortions in Ukraine.

Materials and Methods

Aborted foetuses and/or foetal placentas from cows were selected as samples for the study. As a result, 13 samples were taken, of which two were incomplete: one had no placenta, and the other had no foetus.

Aborted foetuses and the foetal part of placentas were obtained from farms in Cherkasy (3 samples), Kyiv

(3 samples), Khmelnytskyi (4 samples), Sumy (1 sample), Chernihiv (1 sample), and Ternopil (1 sample). The term of pregnancy at which the abortion occurred was set according to the data specified in the attached documents.

The selection of samples for genetic, molecular, and histological research was performed directly in the section hall of “Veterinary Diagnostics Centre” LLC (Kyiv) during the autopsy.

The selection of samples for genetic, molecular, and histological research was performed directly in the section hall of “Veterinary Diagnostics Centre” LLC (Kyiv) during the autopsy. For this, the brain, heart, lungs, spleen, liver, kidneys, skeletal muscles of the neck, and cotyledons of the placenta were selected. Pieces sized 1-1.5 cm were cut from the organs under study, at the border of normal and pathologically changed tissue.

To fix pathological material, pieces of organs were transferred to 10% buffered formalin (Leica, Germany) and kept in it for at least 48 hours. After fixation, pieces sized 0.5×0.5 mm were cut from the selected organs with a blade (considering the specific features of the structure of each organ and the presence of visible pathological changes) and placed in plastic cassettes, which were labelled according to the assigned number. Next, primary processing of the material (dehydration in ethyl alcohol and sealing in liquid paraffin) was performed using a histoprocessor STP-120 (Microm, Germany). The duration of primary tissue treatment was 12 hours [28].

To produce paraffin blocks, a station for filling tissues with paraffin EC 350 (Microm, Germany) was used. For this, tissue samples were transferred to special metal moulds and filled with hot paraffin. After cooling the paraffin on cryo-console, the resulting paraffin blocks were cut on a rotary Microtome HM 340E (Microm, Germany), while the cut thickness was 4 µm. The sections were transferred to slides and dried in a thermostat for 2 hours at 47°C. After drying, they were stained with haematoxylin and eosin (Leica, Germany) according to the generally accepted staining method, and placed in a fixing medium for the manufacture of permanent preparations (Thermo Fisher, USA) [28; 29].

Histological analysis of all samples was performed at magnifications of x100, x200, x400, and x1000 using an Axioskop 40 light microscope (Carl Zeiss, Germany), W-PI 10x/23 glasses, and 10, 20, 40, 100 objectives. Canon PC 1049 Power Shot G5 camera, 5.0 MegaPixels through Adapter tube BAYONET-52 mm (EASY FIT) for Canon G3 (Canon, Japan) was used for photo registration.

In all the samples under study, prior to histological examination, *N. caninum* DNA was detected by polymerase chain reaction. The amplification reaction was carried out using commercial test kits of European manufacturers on QuantStudio 5 Real Time PCR System equipment (Thermo Fisher Scientific, USA), following the manufacturer’s recommendations.

Results and Discussion

Abortions in cows were registered: at 4 months of gestation – five samples, at 5 months – three, at 6 months – four, and at 7 months – one (Table 1).

Table 1. The main pathohistological changes in aborted foetuses and the foetal part of the placenta of cows, considering the pregnancy period

Duration of pregnancy	Number of samples	Pathohistological changes	Number of affected samples	Percentage of affected samples, %
Month 4	5	Encephalitis	4	80
		Myocarditis	4	80
		Myositis	5	100
		Hepatitis	3	60
		Placentitis	4	80
Month 5	3*	Encephalitis	1	50
		Myocarditis	2	100
		Myositis	1	50
		Hepatitis	2	100
		Placentitis	2	67
Month 6	4**	Encephalitis	3	75
		Myocarditis	4	100
		Myositis	3	75
		Hepatitis	3	75
		Placentitis	2	67
Month 7	1	Encephalitis	1	100
		Myocarditis	1	100
		Hepatitis	1	100
		Placentitis	1	100

Note: * – one foetus is missing; ** – one placenta is missing

Focal gliosis (Fig. 1) and perivascular mononuclear infiltrates were found in the brain of six foetuses, and perivascular, perineuronal oedema and perivascular mononuclear infiltrates were found in two. In other foetuses, multiple sites of necrosis, perivascular mononuclear infiltrates, single necrotic neurons, focal necrosis, and perivascular mononuclear infiltrates in its soft shell were also noted in the brain.

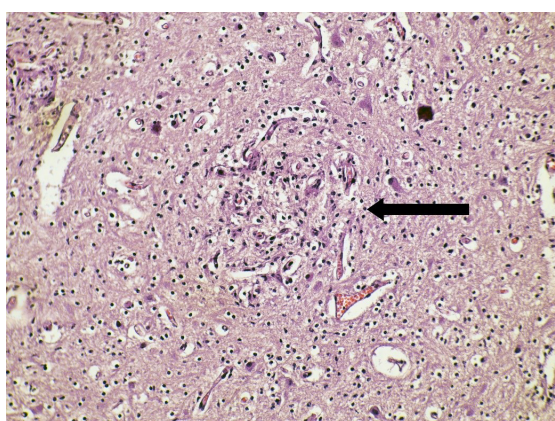


Figure 1. Focus of gliosis in the grey matter of the foetal brain (arrow). Haematoxylin-eosin, ×200

In the hearts of five foetuses, diffuse mononuclear infiltration in the pericardium (Fig. 2), myocardium, and endocardium was recorded, in two – diffuse mononuclear infiltration in the pericardium and myocardium, in four – diffuse mononuclear infiltration in the myocardium (Fig. 3).

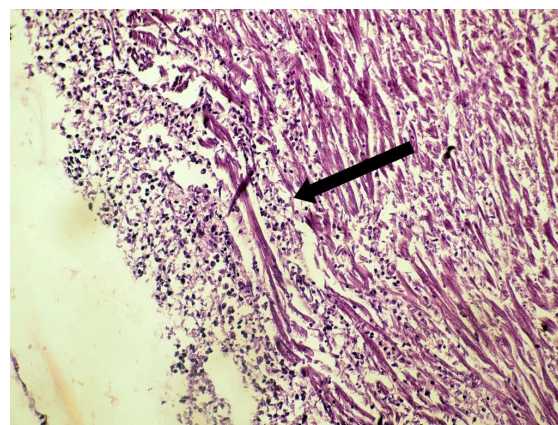


Figure 2. Diffuse mononuclear infiltration in the foetal pericardium (arrow). Haematoxylin-eosin, ×200

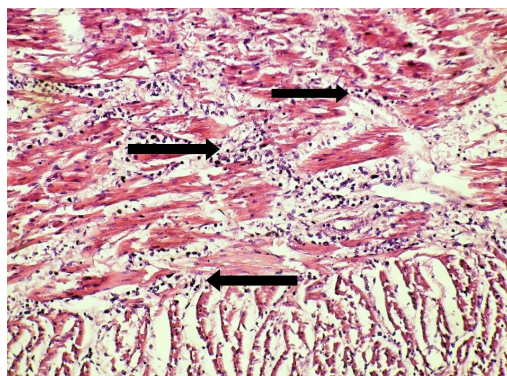


Figure 3. Diffuse mononuclear infiltration in the foetal myocardium (arrows). Haematoxylin-eosin, ×200

Mononuclear infiltration of the interstitium was found in the lungs of two foetuses, focal desquamation of the epithelium of the bronchi and bronchioles, and diffuse lymphocytic alveolitis in another two. Therewith, periportal mononuclear infiltrates were noted in the liver of nine foetuses (Fig. 4), in three – focal necrosis of hepatocytes and in two – focal dystrophy of hepatocytes.

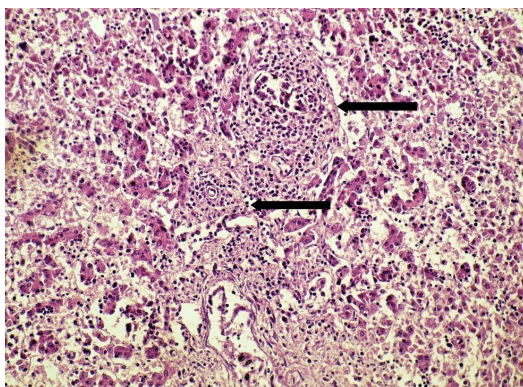


Figure 4. Periportal mononuclear infiltrates in the foetal liver (arrows). Haematoxylin-eosin, ×200

No changes were found in the spleen of twelve foetuses. The skeletal neck muscles of seven foetuses were characterized by diffuse mononuclear infiltration (Fig. 5), for two – focal mononuclear infiltration.

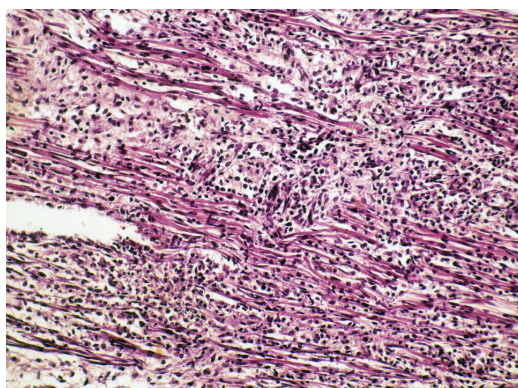


Figure 5. Diffuse mononuclear infiltration in the skeletal muscle of the foetal neck. Haematoxylin-eosin, ×200

Single neosporous cysts and focal mononuclear infiltrates were found in the tongue muscles of one foetus (Fig. 6).

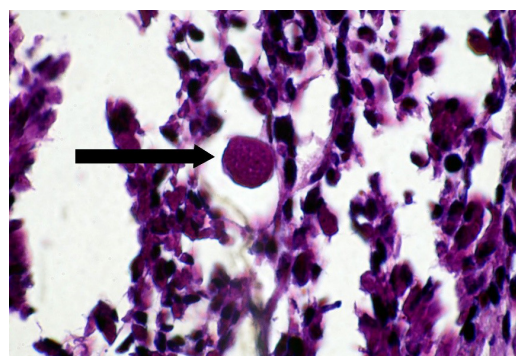


Figure 6. Neosporous cyst in the foetal tongue muscles (arrow). Haematoxylin-eosin, ×1000

Furthermore, diffuse interstitial mononuclear infiltration was diagnosed in the kidneys of three foetuses (Fig. 7), and focal necrosis in one foetus.

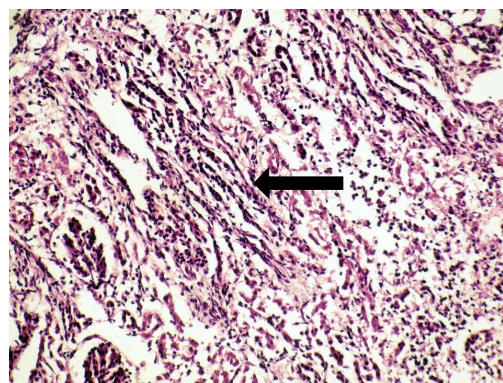


Figure 7. Diffuse interstitial mononuclear infiltration in the foetal kidney (arrow). Haematoxylin-eosin, ×200

In five foetal placentas, focal necrosis of the mucous membrane was established, in three – fibrin deposition on the mucous membrane, and in nine more – focal mononuclear infiltration.

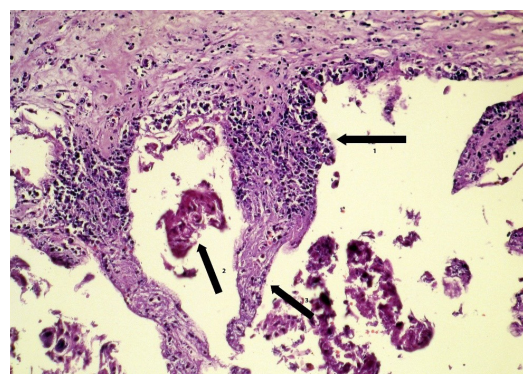


Figure 8. Focal mononuclear infiltration (Arrow 1), deposition of fibrin on the mucous membrane (Arrow 2) and focal necrosis of the mucosal villi (Arrow 3) of the foetal part of the placenta (cotiledon) of the foetus. Haematoxylin-eosin, ×200

Thus, in general, encephalitis was diagnosed in 9 foetuses, meningitis – in 1, pericarditis – in 7, myocarditis – in 11,

endocarditis – in 5, myositis – in 9, hepatitis – in 9, pneumonia – in 4, nephritis – in 3, and placentitis – in 9 (Fig. 9).

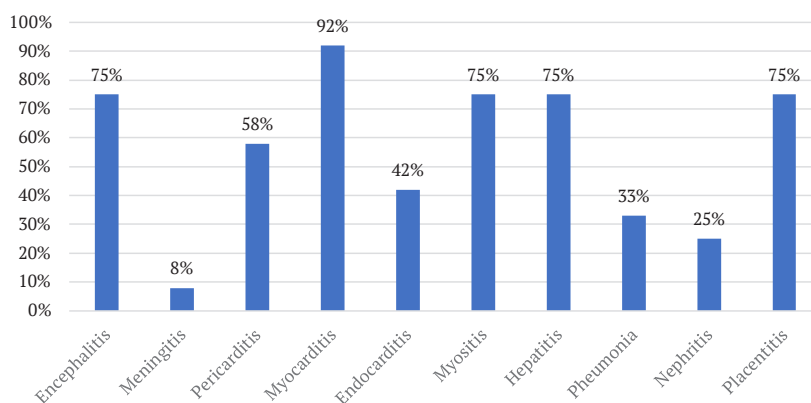


Figure 9. Pathohistological changes in aborted foetuses and foetal part of cow placentas

Regardless of the term of pregnancy, aborted foetuses were mainly diagnosed with encephalitis, myocarditis, myositis, hepatitis, and placentitis (Table 1).

Pathohistological changes (encephalitis, myositis, myocarditis, hepatitis, placentitis), which were detected in most of the foetuses and the foetal part of placentas under study (Table 1), are characteristic of infection caused by *N. caninum* and are consistent with the results of similar studies [12; 13; 17]. Pericarditis, endocarditis, pneumonia, nephritis, and meningitis were somewhat less common. Mononuclear infiltration was present in all organs except the spleen. There were also no changes in the spleen of 12 foetuses and no reports describing them, although the organ itself was selected for research.

The changes mentioned above are non-specific. They are also noted for Bovine viral diarrhoea virus (BVDV) and infectious bovine rhinotracheitis (IBR) in an aborted foetus [32; 33].

Single neosporous cysts were found in only 1 out of 12 foetuses. These results correspond to the results of other researchers, where tissue cysts of *N. caninum* were found extremely rarely during histological examination in foetuses and placentas [20; 30]. Furthermore, the established single neosporous cysts were localized in the muscles of the tongue, while other researchers usually noted them in the brain [15; 30; 34].

Pathohistological changes noted in various organs and systems of aborted foetuses may indicate that the infection caused by *N. caninum* has a systemic manifestation.

Dependence and significant differences between the detected pathohistological changes and the duration of pregnancy at which abortion occurred in cows were not noted. As for the duration of pregnancy, abortions in cows were recorded mainly in the period from 4 to 6 months, although they can also occur from 3 to 9 months of pregnancy [17; 20].

The observed characteristic changes confirm the involvement of *N. caninum* in abortions in cows in livestock farms of Cherkasy, Kyiv, Khmelnytskyi, Sumy, Chernihiv, and Ternopil regions of Ukraine.

The study applied two research methods. First, the

polymerase chain reaction as the most accurate and sensitive method. However, it is not sufficient to confirm the role of *N. caninum* in abortion since there is a high probability of participation or complicity of other factors that can provoke abortion. The histological method allowed identifying changes inherent in neosporosis, but in the absence of specific changes, it cannot be said that they are caused by *N. caninum*. These methods are successfully used in obstetric practice to find the causes of abortions in cows [31]. Therefore, to establish a final diagnosis, the authors of this study recommend the comprehensive use of two research methods at once, as this affects the speed of decision-making and the organization of measures to prevent the spread of neosporosis and its consequences.

Conclusions

It was found that abortions in cows with neosporosis are mainly recorded in the second trimester of pregnancy. Most frequently, pathohistological changes are detected in the brain, heart, skeletal muscles of the neck, liver, and the foetal part of the placenta. Basically, diffuse mononuclear infiltration is noted in the organs of aborted foetuses and the foetal part of placentas of cows. Therewith, as a result of the conducted studies, neosporosis was confirmed as one of the causes of abortions in cows from six regions of Ukraine. It was found that the histological method of examination cannot be used in isolation to establish a definitive diagnosis, since pathohistological changes in neosporosis are non-specific and may be misinterpreted. Therefore, to diagnose this disease in animals, it is recommended to combine two methods: polymerase chain reaction and histological studies.

The results obtained can be used to improve the laboratory diagnosis of neosporosis in cows, control its spread in livestock farms, and develop instructions for further prevention of this disease.

Acknowledgements

The authors highly appreciate the cooperation and financial support of these studies by the owners of cattle farms. The authors also hereby state that they have no conflict of interest.

References

- [1] Donahoe, S.L., Lindsay, S.A., Krockenberger, M., Phalen, D., & Šlapeta, J. (2015). A review of neosporosis and pathologic findings of *Neospora caninum* infection in wildlife. *International Journal for Parasitology: Parasites and Wildlife*, 4(2), 216-238. doi: 10.1016/j.ijppaw.2015.04.002.

- [2] Dubey, J.P., Schares, G., & Ortega-Mora, L.M. (2007). Epidemiology and control of neosporosis and *Neospora caninum*. *Clinical Microbiology Reviews*, 20(2), 323-367. doi: 10.1128/cmr.00031-06.
- [3] Wilson, D.J., Orsel, K., Waddington, J., Rajeev, M., Sweeny, A.R., Joseph, T., Grigg, M.E., & Raverty, S.A. (2016). *Neospora caninum* is the leading cause of bovine foetal loss in British Columbia, Canada. *Veterinary Parasitology*, 218, 46-51. doi: 10.1016/j.vetpar.2016.05.031.
- [4] Nayeri, T., Moosazadeh, M., Sarvi, S., & Daryani, A. (2022). *Neospora caninum* infection in aborting bovines and lost foetuses: A systematic review and meta-analysis. *PLOS One*, 17(5), article number e0268903. doi: 10.1371/journal.pone.0268903.
- [5] Reichel, M.P., Wahl, L.C., & Ellis, J.T. (2020). Research into *Neospora caninum* – What have we learnt in the last thirty years? *Pathogens*, 9(6), article number 505. doi: 10.3390/pathogens9060505.
- [6] Bjerkås, I., Mohn, S.F., & Presthus, J. (1984). Unidentified cyst-forming Sporozoon causing encephalomyelitis and myositis in dogs. *Parasitology Research*, 70(2), 271-274. doi: 10.1007/bf00942230.
- [7] Dubey, J.P., Carpenter, J.L., Speer, C.A., Topper, M.J., & Uggla, A. (1988). Newly recognized fatal protozoan disease of dogs. *Journal of the American Veterinary Medical Association*, 192, 1269-1285.
- [8] Conrad, P.A., Barr, B.C., Sverlow, K.W., Anderson, M.L., Daft, B., Kinde, H., Dubey, J.P., Munson, L., & Ardans, A. (1993). *In vitro* isolation and characterization of a *Neospora* sp. from aborted bovine foetuses. *Parasitology*, 106, 239-249.
- [9] Dubey, J.P., & Schares, G. (2011). Neosporosis in animals – The last five years. *Veterinary Parasitology*, 180(1-2), 90-108. doi: 10.1016/j.vetpar.2011.05.031.
- [10] Williams, D.J.L., Hartley, C.S., Björkman, C., & Trees, A.J. (2009). Endogenous and exogenous transplacental transmission of *Neospora caninum* – How the route of transmission impacts on epidemiology and control of disease. *Parasitology*, 136(14), 1895-1900. doi: 10.1017/s0031182009990588.
- [11] de Souza Ramos, I.A., da Silva, R.J., Maciel, T.A., Afonso da Silva, J.A.B., Fidelis Junior, O.L., Soares, P.C., Machado, R.Z., André, M.R., & de Mendonça, C.L. (2016). Assessment of transplacental transmission of *Neospora caninum* in dairy cattle in the Agreste region of Pernambuco. *Brazilian Journal of Veterinary Parasitology*, 25(4), 516-522. doi: 10.1590/s1984-29612016055.
- [12] Chryssafidis, A.L., Cantón, G., Chianini, F., Innes, E.A., Madureira, E.H., Soares, R.M., & Gennari, S.M. (2014). Abortion and foetal lesions induced by *Neospora caninum* in experimentally infected water buffalos (*Bubalus bubalis*). *Parasitology Research*, 114(1), 193-199. doi: 10.1007/s00436-014-4178-0.
- [13] Dubey, J.P., Buxton, D., & Wouda, W. (2006). Pathogenesis of bovine neosporosis. *Journal of Comparative Pathology*, 134(4), 267-289. doi: 10.1016/j.jcpa.2005.11.004.
- [14] Dubey, J.P., Hemphill, A., Calero-Bernal, R., & Schares, G. (2017). *Neosporosis in animals*. Boca Raton: CRC Press. doi: 10.1201/9781315152561.
- [15] Kim, J.H., Lee, J.K., Lee, B.C., Park, B.K., Yoo, H.S., Hwang, W.S., Shin, N.R., Kang, M. S., Jean, Y.H., Yoon, H.J., Kang, S.K., & Kim, D.Y. (2002). Diagnostic survey of bovine abortion in Korea: With special emphasis on *Neospora caninum*. *Journal of Veterinary Medical Science*, 64(12), 1123-1127. doi: 10.1292/jvms.64.1123.
- [16] Morales, E., Trigo, F.J., Ibarra, F., Puente, E., & Santacruz, M. (2001). Neosporosis in Mexican dairy herds: Lesions and immunohistochemical detection of *Neospora caninum* in foetuses. *Journal of Comparative Pathology*, 125(1), 58-63. doi: 10.1053/jcpa.2001.0477.
- [17] Pereira-Bueno, J., Quintanilla-Gozalo, A., Pérez-Pérez, V., Espi-Felgueroso, A., Álvarez-García, G., Collantes-Fernández, E., & Ortega-Mora, L.M. (2003). Evaluation by different diagnostic techniques of bovine abortion associated with *Neospora caninum* in Spain. *Veterinary Parasitology*, 111(2-3), 143-152. doi: 10.1016/s0304-4017(02)00361-8.
- [18] Nematollahi, A., Moghaddam, G.H., Jaafari, R., Helan, J.A., & Norouzi, M. (2013). Study on outbreak of *Neospora caninum*-associated abortion in dairy cows in Tabriz (Northwest Iran) by serological, molecular and histopathologic methods. *Asian Pacific Journal of Tropical Medicine*, 6(12), 942-946. doi: 10.1016/s1995-7645(13)60168-6.
- [19] Kamali, A., Seifi, H.A., Movassaghi, A.R., Razmi, G.R., & Naseri, Z. (2014). Histopathological and molecular study of *Neospora caninum* infection in bovine aborted foetuses. *Asian Pacific Journal of Tropical Biomedicine*, 4(12), 990-994. doi: 10.12980/apjtb.4.201414b378.
- [20] Collantes-Fernández, E., Rodríguez-Bertos, A., Arnáiz-Seco, I., Moreno, B., Aduriz, G., & Ortega-Mora, L.M. (2006). Influence of the stage of pregnancy on *Neospora caninum* distribution, parasite loads and lesions in aborted bovine foetuses. *Theriogenology*, 65(3), 629-641. doi: 10.1016/j.theriogenology.2005.06.003.
- [21] Georgieva, D.A., Prelezov, P.N., & Koinarski, V.T. (2006). *Neospora caninum* and neosporosis in animals – A review. *Bulgarian Journal of Veterinary Medicine*, 9(1), 1-26.
- [22] De Barros, L.D., Bogado, A.L.G., Furlan, D., de Melo Jardim, A., Okano, W., da Silva, L.C., Pereira, C.E.S., Bronkhorst, D.E., Cardim, S.T., & Garcia, J.L. (2021). Effects of *Neospora caninum* on reproductive parameters in dairy cows from a closed herd in Brazil. *Veterinary Parasitology: Regional Studies and Reports*, 23, article number 100524. doi: 10.1016/j.vprsr.2020.100524.
- [23] Lefkaditis, M., Mpairamoglou, R., Sossidou, A., Spanoudis, K., & Tsakiroglou, P. (2019). *Neospora caninum*, A potential cause of reproductive failure in dairy cows from Northern Greece. *Veterinary Parasitology: Regional Studies and Reports*, 19, article number 100365. doi: 10.1016/j.vprsr.2019.100365.
- [24] Demir, P.A., Eşki, F., & Ütük, A.E. (2020). Estimating the total economic costs of *Neospora caninum* infections in dairy cows in Turkey. *Tropical Animal Health and Production*, 52(6), 3251-3258. doi: 10.1007/s11250-020-02351-1.
- [25] Moore, D., Reichel, M., Spath, E., & Campero, C. (2013). *Neospora caninum* causes severe economic losses in cattle in the humid pampa region of Argentina. *Tropical Animal Health and Production*, 45(5), 1237-1241. doi: 10.1007/s11250-013-0353-z.

- [26] Reichel, M.P., Ayanegui-Alcérreca, M.A., Gondim, L.F.P., & Ellis, J.T. (2013). What is the global economic impact of *Neospora caninum* in cattle – The billion dollar question. *International Journal for Parasitology*, 43(2), 133-142. doi: 10.1016/j.ijpara.2012.10.022.
- [27] Nyzhnyk, B.Y., Valchuk, O.A., Kataieva, T.O., & Zaritskiy, R.V. (2020). Prevalence of cows abortions of infectious etiology in Ukraine. *Ukrainian Journal of Veterinary Sciences*, 11(1), 161-167. doi: 10.31548/ujvs2020.01.017.
- [28] Bahrii, M.M., Dibrova, V.A., Popadynets, O.H., & Hryshchuk, M.I. (2016). *Methods of morphological research*. Vinnytsia: Nova Knyha.
- [29] Horalskiy, L.P., Khomych, V.T., & Kononskiy, O.I. (2005). *Fundamentals of histological technique and morphofunctional research methods in normal and in pathology*. Zhytomyr. Polissia.
- [30] Salehi, N., Haddadzadeh, H., Ashrafihelan, J., Shayan, P., & Sadrebazzaz, A. (2009). Molecular and pathological study of bovine aborted fetuses and placenta from *Neospora caninum* infected dairy cattle. *Iranian Journal of Parasitology*, 4(3), 40-51.
- [31] Melendez, P., Ilha, M., Woldemeskel, M., Graham, J., Coarsey, M., Baughman, D., Whittington, L., & Naikare, H. (2020). An outbreak of *Neospora caninum* abortion in a dairy herd from the State of Georgia, United States. *Veterinary Medicine and Science*, 7(1), 141-147. doi: 10.1002/vms3.346.
- [32] Perotta, J.H., de Freitas, B.B., Marcom, N.N., Pescador, C.A., Pereira, C.C., Locatelli-Dittrich, R., Brum, J.S., & de Barros Filho, I.R. (2021). An abortion storm in dairy cattle associated with neosporosis in southern Brazil. *Brazilian Journal of Veterinary Parasitology*, 30(2), article number e001821. doi: 10.1590/s1984-29612021045.
- [33] Brower, A., Homb, K.M., Bochsler, P., Porter, R., Woods, K., Ubl, S., & Toohey-Kurth, K. (2008). Encephalitis in aborted bovine fetuses associated with *Bovine herpesvirus 1* infection. *Journal of Veterinary Diagnostic Investigation*, 20(3), 297-303. doi: 10.1177/104063870802000306.
- [34] Moroni, M., Navarro, M., Paredes, E., Romero, A., Alberdi, A., Lischinsky, T., & Uzal, F. (2018). Identification of *Neospora caninum* in aborted bovine fetuses of Southern Chile. *Brazilian Journal of Veterinary Pathology*, 11(2), 37-41. doi: 10.24070/bjvp.1983-0246.v11i2p37-41.

Патогістологічні зміни в абортіваних плодів корів за неоспорозу в Україні

Богдан Юрійович Нижник¹, Інна Володимирівна Грушковська²,
Тетяна Олегівна Катаєва², Олександр Анатолійович Вальчук¹

¹Національний університет біоресурсів і природокористування України
03041, вул. Героїв Оборони, 15, м. Київ, Україна

²ТОВ «Центр Ветеринарної Діагностики»
03022, вул. Кайсарова, 15а, м. Київ, Україна

Анотація. Неоспороз – паразитарна хвороба, яка у корів характеризується абортами та народженням слабкого потомства. Збудник *Neospora caninum* – облігатний, найпростіший паразит, який відноситься до типу *Apicomplexa*. Актуальність дослідження зумовлена негативним впливом на економіку (втрата продуктивності, ветеринарні та діагностичні витрати) та недостатнім дослідженням неоспорозу в Україні. У зв'язку з цим, метою роботи було встановлення патогістологічних змін у абортіваних плодів і плодової частини плацент та підтвердження участі паразита (*Neospora caninum*) у випадках абортів, які зафіксовано в різних областях країни. Для дослідження цієї проблеми використовували два методи: гістологічний та полімеразної ланцюгової реакції в реальному часі. У позитивних щодо *N. caninum* абортіваних плодів найчастіше виявляли такі патогістологічні зміни: осередковий гліоз і периваскулярні мононуклеарні інфільтрати в головному мозку; осередкову або дифузну мононуклеарну інфільтрацію в серці та скелетних м'язах; перипортальні мононуклеарні інфільтрати в печінці; осередковий некроз слизової оболонки та мононуклеарну інфільтрацію у плодової частині плацент. Рідше зміни виявляли в легенях – мононуклеарна інфільтрація інтерстиції й дифузний лімфоцитарний альвеоліт, та нирках – дифузна інтерстиціальна мононуклеарна інфільтрація. У селезінці змін не встановлено. Неоспороподібні цисти виявлені в одному з дванадцятьох плодів. Встановлені ураження органів плодів і плацент є характерними для неоспорозу. Результати гістологічних досліджень істотно доповнюють дані інших авторів, підтверджують причетність *N. caninum* до виникнення абортів у корів окремих областей України, а також становлять практичну цінність для діагностики та здійснення контролю за неоспорозом у великої рогатої худоби

Ключові слова: велика рогата худоба, *Neospora caninum*, аборт, гістологія